

RESEARCH ARTICLES

Assessment of the Level of Knowledge and Awareness of Dentists About Antibiotic Prophylaxis

Selen ONAT, Senanur DURUAY, Alptuğ KENDİRCİ,
Serhat POLAT, Nur ALTIPARMAK,

Evaluation of the Prevalence of Temporomandibular Joint Disorder and Bruxism in Individuals with Obstructive Sleep Apnea Syndrome

Cansu Gül KOCA, Bengisu YILDIRIM, Muhammed Fatih ÇİÇEK

CASE REPORTS

Patient-Fitted Total Temporomandibular Joint Prosthesis: A Case Series

Seçil ÇUBUK, Palin ÇİFTÇİOĞLU, Burak BAYRAM

Conservative Management of Large Dentigerous Cysts in Children

Ayşe OZCAN KUCUK, Mahmut KOPARAL, Aydın KESKINRUZGAR

Mandible-first sequence approach in bimaxillary orthognathic surgery using 3D printed surgical templates for facial asymmetry

Cihan VAROL, Yavuz FINDIK, Timuçin BAYKUL, Gülperi KOÇER,
Mehmet Fatih ŞENTÜRK, Tayfun YAZICI, Mustafa Yasin YETER

Maxillary Midpalatal Sagittal Fracture: A Case Report

Çiğdem ÇETİN GENÇ

Primary Intraosseous Squamous Cell Carcinoma Coexisting with a Radicular Cyst: Case Report

Merve ARICI, Okan DURAN, Orçun TOPTAŞ, Çetin BORAN

Dentigerous Cyst Associated with Ectopic Canine of the Maxilla: A Case Report

Rıdvan GÜLER, Bekir İLYAS, Kamil Serkan AĞAÇAYAK

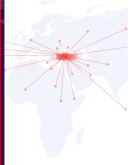Diagnostic Handicap: RHABDOMYOSARCOMA

Tolga BAYAR, Ebru Deniz KARSLI, Betül TAŞ ÖZYURTSEVEN,
Metin GÜNGÖRMÜŞ,



EurAsian Journal of Oral and Maxillofacial Surgery

Official publication of AÇBİD
(Association of Oral and Maxillofacial Surgery Society)



e-ISSN: 2687-5497

EDITORIAL BOARD

President, Oral and Maxillofacial Surgery Society
Hakan H. Tüz, PhD
Hacettepe University, Ankara

Editor-in Chief
M.Ercüment Önder, PhD
Kırıkkale University, Kırıkkale

Associate Editor
Timuçin Baykul, PhD
Süleyman Demirel University, Isparta

Hakan H. Tüz, PhD
Hacettepe University, Ankara

Doğan Dolanmaz, PhD
Bezmialem University, Istanbul

Editorial Secretary
Doruk Koçyiğit, PhD
Kırıkkale University, Kırıkkale

Language Editor
Z. Özgür Pektaş, PhD
Private Practice, Adana

Website Editor
Fethi Atıl, PhD
Mersin University, Mersin

Anesthesia Section Editor
A.Tolga Şitilci, MD
Istanbul University, Istanbul

Craniofacial Deformity Section Editor
Hakan H. Tüz, PhD
Hacettepe University, Ankara

Dentoalveolar Surgery Section Editor
Fatih Mehmet Coşkunes, PhD
Kocaeli University, Kocaeli

Implant Surgery Section Editor
Fethi Atıl, PhD
Mersin University, Mersin

Oral Medicine and Pathology Section Editor
Ceyda Özçakır Tomruk
Yeditepe University, Istanbul

Tissue and Bioengineering Section Editor
Doğan Dolanmaz, PhD
Bezmialem University, Istanbul

TMJ/Facial Pain Section Editor
Umut Tekin, PhD
Kırıkkale University, Kırıkkale

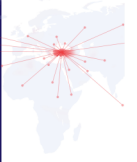Trauma Section Editor
Doruk Koçyiğit, PhD
Kırıkkale University, Kırıkkale



EurAsian Journal of Oral and Maxillofacial Surgery

Official publication of AÇBİD
(Association of Oral and Maxillofacial Surgery Society)

EurAsian Journal of
Oral and Maxillofacial Surgery



ADVISORY BOARD

Gülsüm Ak
Cemal Akay
Nihat Akbulut
Sıdıka Sinem Akdeniz
Alper Aktaş
Hilal Alen
Alper Alkan
Serpil Altundoğan
Ayşegül Apaydın
Kenan Araz
Ahmet Hamdi Arslan
Hanife Ataoğlu
Yavuz Sinan Aydınтуğ
Selçuk Basa
Burcu Baş
Gürkan Raşit Bayer
Burak Bayram
Emel Bulut
Mine Cambazoğlu
Ülkem Cilasun
Figen Çizmeci Şenel
Ezher Hamza Dayısoylu
Ömür Dereci
Gühan Dergin
Ercan Durmuş
Özgür Erdoğan
Sertan Ergun
Behçet Erol
Alparslan Esen
Emin Esen
Yavuz Fındık
Hasan Garip
Mehmet Kamil Göker

Onur Gönül
Nurhan Güler
Belgin Gülsün
Sevtap Günbay
Ahmet Muhtar Gürol
Kubilay Işık
Onur İçten
Abdullah Kalaycı
Beyza Kaya
Kıvanç Bektaş Kayhan
Erdem Kılıç
Adnan Kılınç
Reha Kişnişçi
Hülya Koçak Berberoğlu
Gülperi Koçer
Mahmut Koparal
Meltem Koray
Mehmet Kürkcü
Nükhet Kütük
Deniz Gökçe Meral
Asriye Mocan
Mehtap Muğlalı
Bora Özden
Nedim Özer
Özkan Özgül
Aydın Özkan
Nilüfer Özkan
Yaşar Özkan
Alper Pampu
Mustafa Ramazanoğlu
Alp Saruhanoğlu
Turgay Seçkin
Fırat Selvi

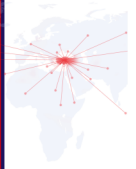Bahar Sezer
Berkay Tolga Süer
Metin Şençimen
Göksel Şimşek Kaya
Hakkı Tanyeri
Fatih Taşkesen
Emre Tosun
Ufuk Toygar Memikoğlu
Funda Tuğcu
Ayşegül Mine Tüzüner
Sina Uçkan
Cem Üngör
Altan Varol
Mehmet Yaltırık
Gülsün Yıldırım Öz
Nergiz Yılmaz
Nuray Yılmaz Altıntaş
Ümit Yolcu

*Board members above are listed
alphabetically by surname.



EurAsian Journal of Oral and Maxillofacial Surgery

Official publication of AÇBİD
(Association of Oral and Maxillofacial Surgery Society)



RESEARCH ARTICLE

Assessment of the Level of Knowledge and Awareness of Dentists About Antibiotic Prophylaxis

Selen ONAT, DDS, Senanur DURUAY, DDS, Alptuğ KENDİRCİ, DDS, Serhat POLAT, DDS, Nur ALTIPARMAK, DDS, PhD

Başkent University, Faculty of Dentistry, Department of Oral and Maxillofacial Surgery, Ankara, Turkey

Abstract

Purpose

Antibiotic prophylaxis defines the practice of antibiotics prior to surgical or non-surgical procedures to prevent local or systemic bacterial infective complications. Infective endocarditis is a serious infection of the heart valves and endocardium mostly associated with congenital and acquired cardiac defects. It has also been shown that infective endocarditis is associated with bacteremia following dental treatment. The aim of the study is to determine the preferences of dentists for the application of antibiotic prophylaxis and to increase awareness by measuring their level of knowledge.

Material and Methods

This study was carried out in Turkey with dentists and dental students using online. In the survey, which was answered by 417 participants, participants were asked a total of 11 questions in 4 separate sections.

Results

The results of the study showed that the participants most frequently prescribed prophylactic antibiotics in the presence of heart valve prosthesis with 95.5% and a history of previous infective endocarditis with 92.9%, before surgical tooth extraction with 96.4% and implant surgery with 94.1 %. As a prophylactic antibiotic, 66.5% of the participants routinely preferred amoxicillin and 77.1% preferred clindamycin if the patient was allergic to penicillin. Answers regarding prophylactic antibiotic dose and duration were classified according to AHA's 2007 guidelines, and female participants (58%) and dentistry students (78.1 %) gave the highest correct answers accordingly.

Conclusion

With this study, it was once again demonstrated that it is extremely important for physicians to follow current guidelines and minimize the risk of bacteremia by taking detailed anamnesis from the patient, and the need to increase awareness of this issue.

Key Words: Antibiotic prophylaxis, infective endocarditis, bacteremia, dentists' knowledge

Introduction

Prophylaxis: It is a word derived from the verb "prophyláss" in ancient Greek, which means protection from disease, preventive measure while the term "antibiotic prophylaxis" defines the application of antibiotics before surgical or non-surgical procedures in order to prevent local or systemic bacterial infective complications¹. Dentists prescribe antibiotics to treat oral and dental infections or as a prophylactic.

It has been shown that infective endocarditis is associated with bacteremia following dental treatment². Bacterial endocarditis (BE) or infective endocarditis (IE) is a serious infection of the heart valves and endocardium mostly associated with

congenital and acquired cardiac defects. BE usually occurs in patients with heart valve prosthesis. If left untreated, it can damage the heart valves and lead to life-threatening complications. It has been shown that approximately 10% of cases of IE occur with common bacteremia after invasive procedures in individuals prone to the disease³. Individuals with a prosthetic heart valve, a congenital heart defect or a recent history of IE are at risk of developing this disease. BE may occur after bacteremia in patients with predisposing heart lesions⁴. In about 60% of IE cases, it has been recognized that the causative organism is pathogen streptococci, and dental treatments such as tooth extraction, scaling and root surface corrections are a temporary source of bacteremia that leads to BE⁵. However, even in patients with a history of underlying

Corresponding Author: Selen ONAT

Address: Başkent University Oral and Maxillofacial Surgery,

Başkent Üniversitesi Diş Hekimliği Fakültesi 82. Sokak No:26 06490 Bahçelievler/ANKARA

Mobile: +90(538) 859 54 76

E-mail: selen_onat95@hotmail.com

heart disease, the incidence of BE following dental treatments is quite low⁶.

It is remarkably recommended to use antibiotic prophylaxis before starting treatment in at-risk individuals with prosthetic heart valves, congenital heart defects, or a recent history of IE before surgical dental procedures^{4,5}. As a general principle, the recommended standard regimen includes the application of a single dose of antibiotics prior to the necessary dental procedures. If the dose was omitted before the procedure, it is recommended to take it up to 2 hours after the procedure. The prophylaxis regime to be applied according to AHA's 2007 guidelines is shown in Table 1⁷. However, the efficacy of antibiotic prophylaxis applied to patients at risk of IE before dental procedures is still controversial⁸. A study conducted in the United States in 2019 reported that only 19.1% of antibiotics prescribed for prophylaxis prior to dental procedures were suitable for its purpose⁹. The main reason for the debate on the need to prevent unnecessary use and the necessity of prophylaxis is the possibility that unnecessary antibiotic use during dental procedures increases the antibiotic resistance of microorganisms and the risk of developing anaphylactic reactions in the patient¹⁰.

Considering all this information, the aim of this article is to determine the antibiotic prophylaxis application preferences of dentists and to measure their knowledge level, as well as to increase awareness about unnecessary antibiotic use.

Situation	Agent	Regimen: Single Dose 30 to 60 min Before Procedure	
		Adults	Children
Oral	Amoxicillin	2 g	50 mg/kg
Unable to take oral medication	Ampicillin OR Cefazolin or ceftriaxone	2 g IM or IV	50 mg/kg IM or IV
		1 g IM or IV	50 mg/kg IM or IV
Allergic to penicillins or ampicillin—oral	Cephalexin [†] OR Clindamycin OR Azithromycin or clarithromycin	2 g	50 mg/kg
		600 mg	20 mg/kg
		500 mg	15 mg/kg
Allergic to penicillins or ampicillin and unable to take oral medication	Cefazolin or ceftriaxone [†] OR Clindamycin	1 g IM or IV	50 mg/kg IM or IV
		600 mg IM or IV	20 mg/kg IM or IV

IM indicates intramuscular; IV, intravenous.

***Or other first- or second-generation oral cephalosporin in equivalent adult or pediatric dosage.**

†Cephalosporins should not be used in an individual with a history of anaphylaxis, angioedema, or urticaria with penicillins or ampicillin.

Table 1: Prophylaxis Practice According to 2007 AHA Guidelines

Materials and Methods

This study was carried out in Turkey with dentists and dentistry students using the "Survey Monkey" online software between December 2020 and April 2021. The questionnaire was delivered to the participants via e-mail and the questions were answered online. This study was approved by Başkent University Institutional Review Board (Project no: D-KA20/30) and also supported by Başkent University Research Fund. The survey was answered by 417 participants and participants were asked a total of 11 questions in 4 separate sections.

In the first part of the survey, personal information (age, gender, professional experience) was given, and physicians were asked how to monitor a patient who needs antibiotic prophylaxis. In the second part, systemic conditions requiring antibiotic prophylaxis, and in the third part, dental procedures requiring antibiotic prophylaxis were investigated. In the last part of the survey, dentists were asked about their preferred antibiotics, the dose they prescribed, and the duration of treatment.

SPSS 25.00 (Statistical Package for Social Sciences, IBM Inc., USA) tool was used for statistical analysis while the normality control of continuous variables was performed by Kolmogorov-Smirnov test. Differences between groups were evaluated using the Student t-test in normal distribution data, while group comparisons for data not suitable for normal distribution were performed using the Mann Whitney U test. ANOVA test and Tukey Post Hoc test were used in normal distribution data and Kruskal-Wallis h test and Tamhane's post Hoc tests were used in non-normal distribution variables in comparison of more than two groups. Descriptive statistics were identified by giving the mean, standard deviation, minimum and maximum values of the continuous variables. The entire study was conducted within 95% reliability limits and in statistical decisions, the level of $p < 0.05$ was considered an indicator of a significant difference.

Results

The sociodemographic characteristics of our participants are given in Table 2. The average age of the 417 volunteers who participated in our survey was 34.88 ± 12.706 [21-80]. Gender distribution was determined as 187 men (44.8%) and 230 women (55.2%). 34 (8.2%) of the participants were trainee dentists, while 164 (39.4%) had 1 – to – 5 years, 47 (11.3%) had 6 – to-10 years, 35 (8%, 4) had 11-to-15 years, and 137 (33%) had more than 15 years of professional experience. 373 of the participants (89.5%) had previously encountered a patient requiring prophylactic antibiotics to prevent the risk of bacteremia, while 44 (10.5%) had not. Of the physicians who answered the questionnaire, 354 (85%) prescribed antibiotics to their patients to prevent the risk of bacteremia, but 63 (15%) did not previously prescribe them for prophylaxis purposes. 205 (49.1%) participants consulted their patient's doctor before starting the treatment, 206 (49.5%) participants prescribed prophylactic antibiotics, and only 6 (1.4%) participants refused treatment and referred the patient to another physician. No statistically significant difference was observed compared to the responses to this question ($p=0.172$).

	Number	Percent (%)
Gender		
Female	<u>230</u>	<u>55,2</u>
Male	<u>187</u>	<u>44,8</u>
Professional Experience		
Dentistry Students	<u>34</u>	<u>8,2</u>
1-5 years	<u>164</u>	<u>39,4</u>
6-10 years	<u>47</u>	<u>11,3</u>
11-15 years	<u>35</u>	<u>8,4</u>
>15 years	<u>137</u>	<u>33</u>
Encountering a Situation That Needed Prophylaxis Before		
Yes	<u>373</u>	<u>89,5</u>
No	<u>44</u>	<u>10,5</u>
Prescribing Antibiotic Prophylaxis Before		
Yes	<u>354</u>	<u>85</u>
No	<u>63</u>	<u>15</u>
When Prophylactic Antibiotics Are Needed		
Write a consultation	<u>205</u>	<u>49,1</u>
Prescribe antibiotics	<u>206</u>	<u>49,5</u>
Refuse treatment and guidance	<u>6</u>	<u>1,4</u>

Table 2: Sociodemographic characteristics of the participants

Prophylactic antibiotic prescription rates according to medical status and dental procedures are shown in Table 3. Volunteers most frequently prescribed prophylactic antibiotics in the presence of heart valve prosthesis with a rate of 95.5% and a history of previous infective endocarditis with a rate of 92.9%. The lowest rate with 6.6% was observed in arrhythmia response. The dental procedures most frequently prescribed for prophylactic antibiotics were surgical tooth extraction with 96.4% and implant surgery with 94.1%. According to the responses, with a ratio of 1.9%, prosthesis cementation was the preferred dental procedure, with minimal prophylaxis. Participants' choice of prophylactic antibiotics in case of routine and allergies is shown in Table 4. According to the survey, amoxicillin was the most preferred antibiotic for prophylactic purposes by 281 participants (66.5%), followed by penicillin with 125 participants (29.5%). No statistically significant difference was observed between them compared to the professional experience of the volunteers surveyed and the antibiotics they would choose for prophylaxis ($p=0.147$). It has been observed that dentists with professional experience highly prefer amoxicillin. In the case of penicillin allergy, clindamycin with 324 participants (77.1%) and macrolide group antibiotics with 80 participants (19%) were most frequently preferred (Table 4). A statistically significant difference was observed between the professional experience of the survey volunteers and the antibiotics they would choose for prophylaxis in patients with

penicillin allergies ($p=0.000$). When the data were examined, all dentists with professional experience preferred clindamycin for patients with high penicillin allergies, while at low rates they preferred cefazolin and tetracycline (Figure 1). No statistically significant difference was observed compared to the gender of the volunteers surveyed and the antibiotics they would choose for prophylaxis ($p=0.124$).

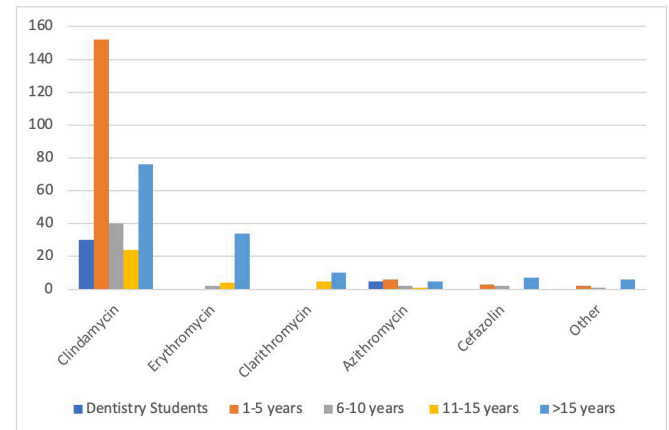


Figure 1: Comparison of the antibiotic to be preferred in patients with penicillin allergy and professional experience

Medical Status	Number	Percent (%)
Presence of a heart valve prosthesis	405	95,5
Presence of stent	136	32,8
Patients who have undergone open heart surgery	217	51,2
Ischemic heart disease	137	32,3
Ventricular septal defect	223	52,6
Atrial septal defect	219	51,7
Rheumatic heart disease	322	75,9
Cyanotic congenital heart disease	196	46,2
Arrhythmia	28	6,6
Previous infective endocarditis	394	92,9
Previous cardiac by-pass operation	136	32,1
Presence of a pacemaker	117	27,6
Mitral valves prolapse or regurgitation	239	56,4
Physiological murmur	40	9,4
Prior heart transplantation	336	79,2
Presence of joint prosthesis	228	53,8
Rheumatoid arthritis	226	53,3
Type I diabetes	89	21
Type II diabetes	71	16,7
Previous kidney transplantation	284	67
Previous liver transplantation	267	63
Dental Procedures		
Simple tooth extraction	299	70,5
Surgical tooth extraction	409	96,4
Periodontal surgery	385	9,8
Implant surgery	399	94,1
Biopsy	292	68,9
Apical resection	382	90,1
Scaling and polishing	181	42,7
Endodontic treatment	198	46,7
Abscess drainage	338	79,7
Dentoalveolar trauma	279	65,8
Fixed orthodontic band placement	109	25,7
Placement of orthodontic brackets	12	2,8
Simple and complex restorations	58	13,7
Tooth preparation and impression taking	139	32,8
Inserting rubber-dam	59	13,9
Matrix band and wedge placement	112	26,4
Intraligamentary anesthesia	178	42
Regional anesthesia	110	25,9
Prosthetic cementation	8	1,9
Suturing	36	8,5

Table 3: Prophylactic antibiotic prescribing rates by medical status and dental procedures

Antibiotic Selection	Number	Percent (%)
Amoxicillin	281	66,3
Penicillin	125	29,5
Clindamycin	9	2,1
Erythromycin	0	0
Clarithromycin	1	0,2
Azithromycin	4	0,9
Cefazolin	2	0,5
Other	2	0,5
In Case of Penicillin Allergy		
Clindamycin	327	77,1
Erythromycin	42	9,9
Clarithromycin	15	3,5
Azithromycin	19	4,5
Cefazolin	11	2,6
Other	10	2,4

Table 4: Rates of antibiotics preferred for prophylaxis in routine and penicillin allergy

As the final question, the preferred dose of prophylactic antibiotics and the duration before the operation were manually filled out by the participants. Responses were determined according to AHA's 2007 guidelines (Table 1) and divided into two groups: "true" and "false". Every answer outside of the manual was deemed false. Those who were left blank were not included in the study for this question. Accordingly, 120 (58%) of women answered correctly, while 87 (42%) answered incorrectly. For men, 91 participants (57.2%) answered correctly, and 68 participants (42.8%) answered incorrectly (Figure 2). Looking at the results, it is quite clear that there is a statistically significant difference between the genders ($p=0.02$).

25 of 32 (78.1%) trainee dentists were correct; 83 of 147 (56.5%) dentists with 1-5 years experienced were correct; 27 of 43 (62.8%) dentists with 6-10 years experienced were correct, and 12 of 25 (48%) 11-15 years experienced dentists were correct; 64 of 119 (53.8%) dentists with more than 15 year experience were correct. No statistically significant difference was observed compared to professional experience ($p=0.102$).

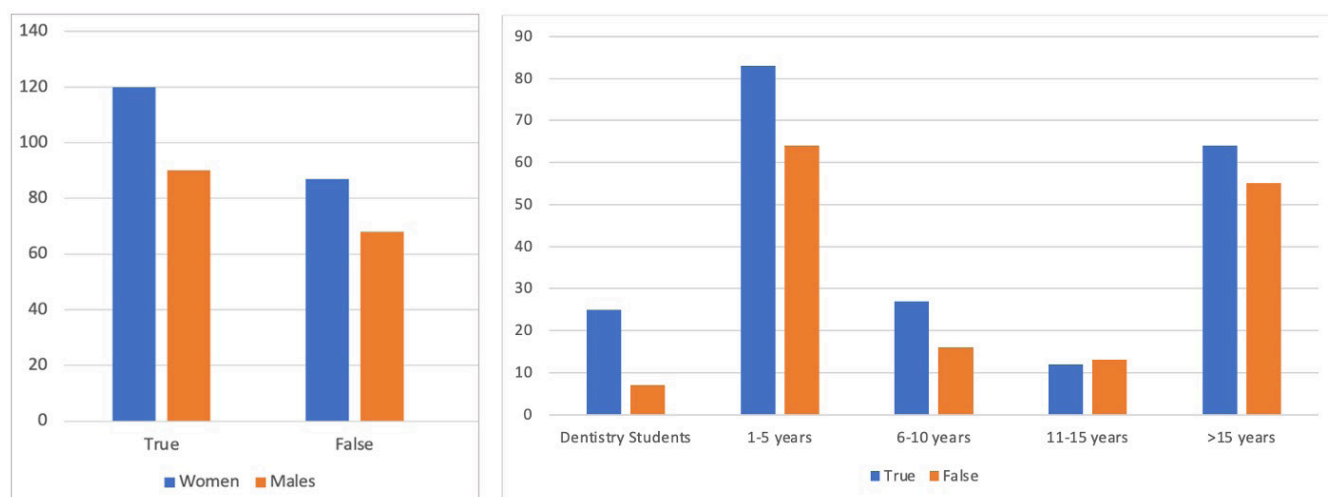


Figure 2a: Comparison of genders and preferred antibiotic dose and duration

Figure 2b: Comparison of preferred antibiotic dose and duration with professional experience

Discussion

Although IE is a rare disease, it is widely known that the prognosis is poor after being affected by this disease¹¹. Studies have shown that even when prophylactic antibiotic regimens are used in all susceptible patients, the rate of IE is reduced by only 3.5%¹². However, in a high-risk population, the risk of developing IE following dental procedures is minimal [1 in 95,000]¹³. In order to minimize this risk, dentists can prescribe consultations to patients' doctors, prescribe antibiotic prophylaxis, or refuse treatment and refer them to another dentist. Karadağ et al. demonstrated that medical consultation for cardiovascular system patients prior to dental treatments increases the success of prophylaxis against IE. They also attributed the reason for this to the fact that cardiologists and infectious disease specialists followed the guidelines on IE more closely¹⁴. In this study, the knowledge, the experience and the awareness of physicians about the antibiotic prophylaxis option were evaluated. 49.1% of our participants consulted the patient, 49.5% prescribed antibiotic prophylaxis, and 1.4% refused the treatment and referred them to another physician. In this research, our aim is to increase the sensitivity and awareness of dentists on this issue.

In the first part of the questionnaire, personal information such as age, gender and professional experience were included. In the second part of the questionnaire, situations requiring antibiotic prophylaxis were investigated. According to the 2007 AHA guidelines, IE antibiotic prophylaxis is recommended; prosthetic heart valve or the presence of prosthetic material used in valve correction, a history of previous IE, heart transplant patients who develop congenital heart disease and cardiac valvulopathy⁷. Our survey also yielded the results that support this. Participants mostly preferred IE prophylaxis in the presence of heart valve prosthesis with 95.5%, in the presence of previous IE with 92.9% and in patients with heart transplantation with 79.2%. In addition, although there is no evidence to support antibiotic prophylaxis in patients with diabetes mellitus, antibiotic prophylaxis is usually recommended¹. The reason for this is to minimize the risk

of potential late wound healing and postoperative infection¹⁵. However, in our study, this rate showed a low result with 21% for type I diabetes and 16.7% for type II diabetes. Diabetes mellitus is a very common disease so increasing the awareness of physicians about prophylaxis in patients with diabetes mellitus is extremely essential for the completion of wound healing without complications.

In the third part of the questionnaire, dental procedures requiring antibiotic prophylaxis were questioned. In general principle, a single dose of antibiotics is recommended before all dental procedures involving manipulation of the gingival tissue or the periapical region of the tooth and perforation of the oral mucosa⁷. These procedures include simple/surgical tooth extraction, endodontic treatment, apical resection, implant applications and preprosthetic surgery, periodontal surgery, biopsy and abscess drainage. Our survey results supported the AHA guidelines and gave the highest results in surgical tooth extraction, implant surgery and periodontal surgery with 96.4%, 94.1% and 90.8%, respectively. Palmer et al. in his study, most of the participants also recommended antibiotic prophylaxis for surgical tooth extraction^[16]. However, although antibiotic prophylaxis was recommended for endodontic treatment, the result in our study was relatively low, with 46.7%.

In the fourth part of the survey, the level of awareness regarding the selection of antimicrobial agents, application time and dosage were evaluated. For 50 years, the AHA has been recommending penicillin as the preferred first choice for IE antibiotic prophylaxis. It is now believed that a single dose of amoxicillin or ampicillin is the appropriate and safe prophylactic choice for patients¹⁷. Recent studies have shown that amoxicillin therapy has a significant effect on reducing the incidence, nature, and duration of bacteremia caused by the dental procedure²⁰. Amoxicillin was the most preferred antibiotic for prophylaxis with 68.3% in the study by Hashemipour et al. and 63.5% in the study conducted by Bahammam et al.^{18,19}. According to our study, amoxicillin with 66.5% and penicillin with 29.5% showed the highest rates. In

addition, the most frequently prescribed prophylactic antibiotic in the case of penicillin allergy was observed as clindamycin with 77.1%, followed by macrolide group antibiotics with 19%, which is quite consistent with other studies.

Although Ghaderi et al.²¹ reported that male dentists were more knowledgeable than female dentists in their study, female physicians were found to be more knowledgeable in terms of prophylactic antibiotic dose and duration in our study. Considering the professional experience, it was seen that the dentistry students gave the highest percentage of correct answers, and this can be associated with the situation in which interns learn the current regime in their training. On the other hand, it should be noted that the number of participants is less than the other groups. The group with the highest percentage of incorrect answers is physicians with 11-15 years of experience.

Conclusion

In conclusion, as a result of the studies, it was clearly seen that physicians applied prophylaxis in past infective endocarditis and heart valve diseases and generally preferred amoxicillin for prophylaxis, and clindamycin instead of penicillin derivatives in patients allergic to penicillin. Furthermore, it is extremely crucial for physicians to follow current guidelines and minimize the risk of bacteremia by taking a detailed anamnesis from patients. Further studies are also needed to increase awareness on this issue.

Declaration of conflicting interests

None.

Funding

This study was supported by Başkent University Research Fund.

Authorship of Contributions

All authors read and approved the final manuscript.

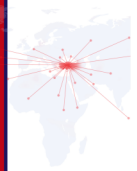References

1. Termine N, Panzarella V, Ciavarella D. Antibiotic prophylaxis in dentistry and oral surgery: use and misuse. *International Dental Journal*. 2009; 59:263-70.
2. Tong DC, Rothwell BR. Antibiotic prophylaxis in dentistry: a review and practice recommendations. *J Am Dent Assoc*. 2000; 131(6):366-74.
3. Solomon M, Raveh D, Schlesinger Y, Yinnon AM. Assessment of knowledge of guidelines for the prevention of infective endocarditis among. *J Hosp Infect*. 2000;45(4):311-7.
4. Pierce D, Calkins BC, Thornton K. Infectious endocarditis: diagnosis and treatment. *Am Fam Physician*. 2012; 85: 981-6.
5. Tierney LM, McPhee SJ, Papadakis MA. *Current Medical Diagnosis and Treatment*. 2002. 41st ed. New York: Lange/Mc Graw Hill; 2002. p. 1410.
6. Tomas Carmona I, Diz Dios P, Limeres Posse J, Outumuro Rial M, Caamano Duran F, Fernandez Feijoo J. Pautas de profilaxis antibiotica de endocaditis bacteriana, recommdadas por los odontologos en spana. *Med Oral*. 2004; 9:56-62.
7. Wilson W, Taubert KA, Gewitz M. Prevention of infective endocarditis: guidelines from the American Heart Association: A guideline from the American Heart Association Rheumatic Fever, Endocarditis, and Kawasaki Disease Committee, Council on Cardiovascular Disease in the Young, and the Council on Clinical Cardiology, Council on Cardiovascular Surgery and Anesthesia, and the Quality of Care and Outcomes Research Interdisciplinary Working Group. *Circulation* 2007;1 16:1736-54.
8. Owen CP, Huang WH. Antibiotic prophylaxis for dental procedures: is it necessary? *SADJ*. 2012;67(7):413-9.
9. Suda J, Calip S, Zhou J, Rowan S, Gross E, Hershow C, Perez I, McGregor C, Evans T. Assessment of the appropriateness of antibiotic prescriptions for infection prophylaxis before dental procedures, 2011 to 2015. *JAMA Network Open*. 2019;2(5): e193909.
10. NICE. Prophylaxis against infective endocarditis: antimicrobial prophylaxis against infective endocarditis in adults and children undergoing interventional procedures. *NICE Clin Guid* 64. 2008;(April 2007).
11. Goldman L, Ausiello D. *Cecil Textbook of Medicine*, 22nd ed. Philadelphia: WB Saunders; 2004:958-967.
12. Lauber C, Compton S, Lalh SS, Grace M, Smith MH, West MH. Antibiotic prophylaxis practices in dentistry: a survey of dentists and physicians. *J Can Dent Assoc*. 2007; 73:263-9.
13. Pallasch TJ. Antibiotic prophylaxis: problem in paradise. *Den Clin N Am*. 2003; 47:665-79.
14. Yılmaz Karadağ F, Şimşek Yavuz S, Cınar Aydın G, Tukenmez Tigen E, Sırmatel F, Karadeniz A, Aydın Ö, Ergen P, Yılmaz N, Cabadak H, Tekin R, Aydın M, Koc MM, Sensoy A, Öcalmaz MS, Timurkaynak F. Assessment of the knowledge and awareness levels of dentists regarding prophylaxis for infective endocarditis. *Med Med J*. 2019;34(1):39-46.
15. Ryalat S, Hassona Y, Al-Shayyab M, Abo-Ghosh M, Sawair F. Dentists' knowledge and practice regarding prevention of infective endocarditis. *Eur J Dent*. 2016;10(4):480-5.
16. Palmer NA, Pealing R, Ireland RS, Martin MV. A study of prophylactic antibiotic prescribing in National Health Service general dental practice in England. *Br Dent J* 2000; 189: 43-46.
17. Mikx FH, König KG, van Rossum GM, Bruers JJ. Prescription of antibiotics for the prevention of bacterial endocarditis by dentists in the Netherlands. *Ned Tijdschr Tandheelkd*. 1995; 102: 337-339.
18. Hashemipour M, Baharlooei K, Mohammadi A. Iranian dentists' knowledge of antibiotic prophylaxis guidelines for prevention of bacterial endocarditis. *Shiraz Univ Den J*. 2007; 8:46-57.
19. Bahammam MA, Abdelaziz NM. Awareness of Antimicrobial Prophylaxis for Infective Endocarditis Among Dental Students and Interns at a Teaching Hospital in Jeddah, Saudi Arabia. *Open Dent J*. 2015; 9:176-80.
20. Lockhart PB, Brennan MT, Kent ML, Norton HJ, Wei-nrib DA. Impact of amoxicillin prophylaxis on the incidence, nature, and duration of bacteremia in children after intubation and dental procedures. *Circulation* 2004; 109: 2878-2884.
21. Ghaderi F, Oshagh M, Dehghani R, Hasanshahi R. Awareness of Iranian's General Dentists Regarding the Latest Prophylaxis Guideline for Prevention of Infective Endocarditis. *J Dent (Shiraz, Iran)*. 2013;14(1):6-12.



EurAsian Journal of Oral and Maxillofacial Surgery

Official publication of AÇBİD
(Association of Oral and Maxillofacial Surgery Society)



RESEARCH ARTICLE

Evaluation of the Prevalence of Temporomandibular Joint Disorder and Bruxism in Individuals with Obstructive Sleep Apnea Syndrome

Cansu Gül KOCA, Assist. Prof.¹, **Bengisu YILDIRIM**, Assist. Prof.², **Muhammed Fatih ÇİÇEK**, Research Assist¹

¹Usak University Dentistry faculty Department of Oral and Maxillofacial Surgery

²Usak University Dentistry faculty Department of Prosthodontics

Abstract

Objective: To evaluate the possible association between obstructive sleep apnea syndrome (OSAS) and temporomandibular disorder (TMD) and bruxism.

Materials-Methods: This study was performed in a group patients with and without OSAS suffering from myofacial pain. All patients were evaluated for TMD with Fonseca Anamnestic Index. The diagnosis of bruxism was made by clinical examination of all patients and in accordance with their anamnesis. Statistical analyses were performed with IBM SPSS statistics [24.0 Version; SPSS Inc, Chicago, IL]. The level of significance was set at $p < 0.05$. Descriptive data were calculated for all variables. Chi square test was used to compare categorical variables.

Results: There were a total of 54 patients suffering from myofacial pain and 28 (51.9%) of the patients were also associated with OSAS. It was observed that the prevalence of bruxism in individuals with OSAS (82%) was significantly higher than individuals without OSAS (15.4%) ($p < 0.001$). Moderate or severe TMD incidence in non-OSAS cases was 15.4%, and all of the cases with OSAS had moderate or severe TMD, and this difference between groups was statistically significant ($p < 0.001$).

Conclusion: As a result of this study, it was seen that there is a strong relationship between OSAS and TMD and bruxism. Although the cause and effect relationship between OSAS and TMD or bruxism has not been proven, in the literature there is a considerably high prevalence for the correlation of these disorders. Additional studies are required in the future, using objective methods and analyzing more patient groups.

Keywords: obstructive sleep apnea syndrome, temporomandibular joint disease, bruxism,

Introduction

Obstructive sleep apnea syndrome (OSAS) constitutes the most important group among sleep-related breathing disorders [1]. The American Sleep Academy defines OSAS as a disease characterized by recurrent apnea or hypopnea during the sleep period, followed by a decrease in blood oxygen saturation and arousals [1]. According to the apnea-hypopnea index (AHI), values below 5 are seen as normal, while AHI is categorized as mild OSAS between 5-15, moderate OSAS between 16-30, and severe OSAS when it is greater than 31 [1]. It is stated that OSAS, which is seen as an important public health problem worldwide, is seen in 9% of males and 4% in females. In the literature, there are many studies regarding effect of OSAS on the stomatognathic system, especially its relationship with temporomandibular joint disorders (TMD) and bruxism.

TMD is an umbrella term that includes all pathological conditions related to temporomandibular joint internal structure, masticatory muscles and related anatomical structures [2,3]. It is defined as the main cause of non-odontogenic pain of the orofacial region and can seriously affect the quality of life [4,5]. The most common clinical symptoms of TMD are osteoarthritis, click-crepitation, mandibular deviation and pain. Etiological factors include trauma, genetic factors and parafunctional habits.

Bruxism is a second title associated with OSAS, and it is also stated to be effective on the stomatognathic system. There are different definitions of bruxism in the current literature. The generally accepted view is that bruxism is a parafunctional habit characterized by rhythmic or irregular nonfunctional clenching and/or grinding. Types of bruxism can be evaluated under two headings as awake bruxism (AD) and sleep bruxism

Corresponding Author: Cansu Gül KOCA

Assist. Prof.

Address: Usak University Dentistry Faculty Department of Oral and Maxillofacial Surgery
Cumhuriyet Mah. Kolej sok. No:3 Uşak Üniversitesi Diş Hekimliği Fakültesi

Mobile: +90(543) 806 9991

e-mail: cansu.koca@usak.edu.tr

(SB) due to etiopathogenesis (6).

Although there are many studies in the literature evaluating the relationship between OSAS and TMD or between OSAS and bruxism, to the authors' knowledge there are only a few studies evaluating the relationship between OSAS and TMD and bruxism in the same study. The aim of this study was to evaluate the relationship between OSAS and TMD and bruxism. The first null hypothesis was that there would be a significant relationship between the severity of OSAS and severity of TMD and the second null hypothesis was that there would be a relation between OSAS and bruxism.

Materials and Methods

Patients aged 18 years and over who applied to the Uşak University Dentistry Faculty Department of Oral and Maxillofacial Surgery between 2019-2021 with the complaint of myofascial pain were included in this study. Ethical approval was obtained by the Non-Interventional Medicine Ethics Committee of Uşak University Faculty of Medicine (06-01-17). The exclusion criteria included a history of TMJ surgery, TMJ local pathology, trauma, or orthognathic surgery, oral appliance using for OSAS treatment, a history of bruxism treatment.

The patients included in the study were evaluated under 2 groups as OSAS and healthy. Participants who were registered in the Sleep Center of the Uşak University Training and Research Hospital Chest Diseases Clinic and were diagnosed with OSAS were included in the OSAS group.

All of the patients included in the study were evaluated for the diagnosis of TMD using the Turkish version of the Fonseca Anamnestic Index (FAI). A questionnaire was used to categorize the severity of TMD. The participants were asked to answer questions without any time restrictions. The value of each answer being "yes = 10," "no = 0," and "sometimes = 5." As a result of the sum of the scores, each patient was classified with an absence of TMD (0-15) and presence of TMD (mild-TMD: 20-45; moderate-TMD: 50-65; severe-TMD: 70-100) (Figure-1) (7-9).

All of the patients were evaluated for the diagnosis of bruxism. According to international consensus recommendations, the diagnosis of 'probable bruxism' was based on self-reports and clinical examination findings (10,11).

Self-reported bruxism questionnaire items were as follows:

- (1) Are you aware that you grind your teeth during sleep?
- (2) Has anyone ever told you that you grind your teeth during sleep?
- (3) Upon awakening in the morning or during the night, do you have your jaws thrust or braced?
- (4) Do you clench your teeth while awake?
- (5) Do you grind your teeth while awake?

The responses to all questions were yes/no.

During the intraoral examination of grinding, the following characteristics were recorded:

- 1) Clenching reported by sleep partners or roommates
- 2) Hyperkeratosis of the cheek mucosa (linea alba)
- 3) Indented tongue
- 4) Unilateral masseter muscle hypertrophy
- 5) Tooth wear
- 6) Hypersensitivity, pain, and morning or daytime fatigue in the chewing muscles

Statistical Analysis

Statistical analysis were performed with IBM SPSS statistics (24.0 Version; SPSS Inc, Chicago, IL). The level of significance was set at $p < 0.05$. Descriptive data were calculated for all variables. Chi square test was used to compare categorical variables.

Results

Among the 54 total patients included in this study, 28 (51.9%) were female, 26 (48.1%) were male. The control group comprised 26 (48.1%) patients without OSAS while, the OSAS group included 28 (51.9%) patients who were diagnosed with OSAS. The average age was 30.2 (± 5.6).

Questions	Yes	No	Sometimes
1. Is it hard for you to open your mouth?			
2. Is it hard for you to move your mandible from side to side?			
3. Do you get tired /muscular pain while chewing?			
4. Do you have frequent headaches?			
5. Do you have pain on the nape or stiff neck?			
6. Do you have earaches or pain in craniomandibular joints?			
7. Have you noticed any TMJ clicking while chewing or when you open your mouth?			
8. Do you clench or grind your teeth ?			
9. Do your feel your teeth do not articulate well?			
10. Do you consider yourself a tense (nervous) person?			

Figure-1: Fonseca Anamnestic Index (FAI) questionnaire

According to the OSAS level classification; moderate OSAS was observed in 17 (31.5%) patients, and severe OSAS was observed in 11 (20.4%) patients. Table-1 shows the relationship between OSAS level and genders and there was no statistically significant difference in the incidence of OSAS between the genders ($p \rightarrow 0.05$).

TMD was absent or mild TMD was observed in 22 (40.7%) patients included in the study, while moderate or severe TMD was observed in 32 (59.2%) patients. TMD was absent or mild in 22 (84.6%) of the cases without OSAS, while moderate or severe TMD was found in 4 (15.4%) patients. Moderate or severe TMD was observed in all patients with OSAS. There was a statistically significant correlation between OSAS severity and TMD level ($p \leftarrow 0.001$) (Table-2).

According to Table-3, 27 (50%) patients included in the study had bruxism, while the other 27 (50%) patients did not have bruxism. While bruxism was observed in 4 (15.4%) patients without OSAS, bruxism could not be diagnosed in 22 (84.6%) patients. While 13 (76.5%) patients with moderate OSAS diagnosed with bruxism and 4 (23.5%) patients did not have bruxism, 10 (90.9%) patients diagnosed with bruxism with severe OSAS, 1 (9.1%) patient did not have bruxism. There was a statistically significant correlation between the severity of OSAS and the incidence of bruxism ($p \leftarrow 0.001$).

Table-1: Comparison of OSAS presence/severity with gender

Female			Genders		Total	*P-VALUE
Male						
OSAS	Absent		14 _a	12 _a	26	0,526
		%	53,8%	46,2%	100,0%	
	Moderate		10 _a	7 _a	17	
		%	58,8%	41,2%	100,0%	
	Severe		4 _a	7 _a	11	
		%	36,4%	63,6%	100,0%	
Total			28	26	54	
%		51,9%	48,1%	100,0%		

*Chi square test

Table-2: Comparison of OSAS presence/severity with TMD presence/severity

Absent/ Mild Moderate Severe			TMD		Total	*P-VALUE
OSAS	Absent		22 _a	4 _b	26	<0.001
		%	84,6%	15,4%	100,0%	
	Moderate		0 _a	17 _b	17	
		%	0,0%	100,0%	100,0%	
	Severe		0 _a	11 _b	11	
		%	0,0%	100,0%	100,0%	
Total			22	32	54	
%		40,7%	59,3%	100,0%		

*Chi square test

Table-3: Comparison of OSAS presence/severity with bruxism

	Bruxism	Present	Absent	TOTAL	*P-VALUE
OSAS	Absent	4 _a	22 _b	26	<0.001
		15,4%	84,6%	100,0%	
	Moderate	13 _a	4 _b	17	
		76,5%	23,5%	100,0%	
	Severe	10 _a	1 _b	11	
		90,9%	9,1%	100,0%	
TOTAL		27	27	54	
50,0%		50,0%	100,0%		

*Chi square test

Discussion

OSAS, which has an important place among sleep disorders, is considered as a major health problem due to its incidence and consequences [12-14]. OSAS can be diagnosed using clinical, medical history and polysomnography (PSG). OSAS can be diagnosed with the help of some questions, as well as by evaluating skeletal and soft tissue abnormalities with cephalometric x-rays taken from the patient [15-17]. In addition, PSG is considered the 'gold standard' for OSAS diagnosis. Due to the retrospective nature of this study, patients diagnosed with OSAS through PSG were included while selecting the patients.

Even though OSAS is associated with many systemic diseases, there is no definite consensus in the literature about its effect on the stomatognathic system. TMD is a broad term used in the definition of pathological conditions seen on the stomatognathic system, which is frequently seen in the population and can adversely affect quality of life by affecting functions such as chewing and speaking [16]. Research diagnostic criteria for temporomandibular disorders (RDC/TMD) scale is generally preferred in the diagnosis of TMD. Even though this scale has a high validity and reliability rate in the diagnosis of TMD, it is not often preferred due to its difficult and time-consuming application protocol, and the fact that it needs to be performed by people with expertise and experience in the field. FAI, on the other hand, was preferred for the diagnosis of TMD in this study because it is fast and easy to perform, does not require expertise or experience, and its validity and reliability in the diagnosis of TMD has been proven by studies conducted [18,19].

Studies have generally stated that there is a relationship between OSAS and TMD regardless of the technique, and there is no definite consensus in the literature on the cause/effect relationship [16]. Smith et al. [20] and Edwards et al. [21] emphasize that this situation causes pain amplification by acting on the central sensitization of the sleep problem. On the other hand, Sander et al. [22] argued that the resistance to inspiration developed during OSAS leads to the development of TMD by causing a decrease in the sensitivity of baroreceptors and deterioration. The general opinion in the literature is that there is a relationship between OSAS and TMD, since both conditions are frequently seen in the population [17]. Smith et

al. [20] reported in their study that one third of the patients with TMD had OSAS. The diagnosis of OSAS was made using PSG, as in this study, and the investigators emphasized that in the clinic, the evaluation of TMD patients as potential OSAS patients should be considered. Zwiri et al. [17] reported that 2% of 100 cases in their clinical study had clear signs and symptoms. Cunali et al. [23] reported that in their study, 52% of the mild to moderate OSAS cases were diagnosed with TMD with RDC/TMD. In this study, TMD was found in all cases (n=28) with moderate and severe OSAS, and in 15.4% (n=4) of cases without OSAS. In other words, the incidence of TMD increases as the severity of OSAS increases, and the findings are consistent with the literature.

Another view on the relationship between OSAS and TMD is stated by Sanders et al. [22] and the authors reported that bruxism is a bridge between OSAS and TMD. The relationship between TMD and bruxism was not examined in this study, and it cannot be said that the study is supported in terms of this hypothesis. Although it is still unclear in the literature that bruxism is a trigger for TMD, it has been reported that the incidence of TMD is significantly higher in individuals with bruxism in recent studies [3]. In addition to this, studies in the literature indicate that another effect of OSAS on the stomatognathic system is through bruxism [24]. In the diagnosis of bruxism, the grading system is grouped under three categories as 'possible', 'probable' and 'definite' [10]. Probable bruxism is established by self-reported intraoral examination. Although PSG is considered the gold standard for the diagnosis of bruxism, it may not always be possible to use pPSG due to limited number of patients, it being an expensive method, and the lack of opportunity to perform it. In addition, since the study was planned retrospectively, bruxism was diagnosed based on the clinical examination and anamnesis of the patients [24]. Additionally, it was stated that it is difficult to distinguish between SB and AB in the diagnosis of bruxism based on clinical examination and anamnesis. Therefore, in this study, cases were evaluated as bruxism without separating them as SB or AB.

In the literature, there is a relationship between OSAS and bruxism, but in terms of cause and effect 2 opinions prevail in the literature; 1- SB usually occurs together with micro-

aurosal that occurs during apnea-hypopnea events or 2-SB is triggered concurrently when the AH events end, but there is no definite consensus on the issue [24].

Jokubauskas and Baltrusaityte [24] evaluated the relationship between OSAS and SB and reported that there is a strong correlation between SB and OSAS. Saito et al. [25] on the other hand, evaluated the relationship between SB and OSAS in their study in 2013 and reported a weak correlation between them. However, there are limitations in this study, such as the lack of a control group, the small number of cases included, and the low mean age. In this study, the incidence of bruxism was observed to be 76.5% (n=13) and 90.9% (n=10) in cases with moderate and severe OSAS respectively, and 15.4% (n=4) in cases without OSAS. In other words, as the severity of OSAS increases, the incidence of bruxism increases significantly and it can be stated that these findings are consistent with the literature.

Although there are many studies in the literature evaluating the relationship between OSAS and TMD or between OSAS and bruxism, there are only a few studies evaluating the relationship between OSAS and both TMD and bruxism. With this study, the relationship between OSAS and both TMD and bruxism was evaluated albeit with some limitations.

One of the limitations is the fact that PSG is not used in the diagnosis of bruxism due to the retrospective nature of the study. Accordingly, the relationship between SB, AB and OSAS could not be evaluated, which is the second limitation.

Conclusion

With this study, it was concluded that TMD and bruxism are seen significantly more in cases where OSAS severity is moderate or severe. In the light of this finding, the authors believe that a prognosis to consider the potential possibility of OSAS in patients diagnosed with TMD and/or bruxism should be taken into consideration in the clinic. Additionally, in the following years, there will be a need for studies in which the relationship between OSAS, TMD and bruxism is evaluated with more patient populations and using more objective methods.

Acknowledgement

Source of Finance No Funding

Conflict of Interest No conflict of interest

References

1. Taş E., Bilazer M., Şahin E., Gürsel A.O. Obstrüktif uyku apne sendromlu hastalarda sefalometrik analiz sonuçları. KBB-Forum 2007; 6(2): 49-56.
2. Abbott M.B., Donnelly L.F., Dardzinski B.J., Poe S.S., Chini B.A., Amin R.S. Obstructive sleep apnea: MR imaging volume segmentation analysis. Pediatric Imaging 2004; 232: 889-895.
3. Koca C.G., Gümrükçü Z., Bilgir E. Does clinical findings correlate with magnetic resonance imaging (MRI) findings in patients with temporomandibular joint (TMJ) pain? A cross sectional study. Med Oral Patol Oral Cir Bucal 2020; 25(4): 495-501.
4. Odaş B., Gündüz Arslan S. Temporomandibular eklem anatomisi ve rahatsızlıkları. Dicle Tıp Dergisi. 2008; 35(1): 77-85.
5. Bonato L.L., Quinelato V., De Felipe Cordeiro P.C., De Sousa E.B., Tesch R., Casado P.L. Association between temporomandibular disorders and pain in other regions of the body. Journal of Oral Rehabilitation 2016; 44(1): 9-15.
6. Koca C.G., Yıldırım B., Bilgir E. Effects of bruxism on temporomandibular joint internal derangement in patients with unilateral temporomandibular joint pain: The role of magnetic resonance imaging diagnostics. CRANIO 2021 DOI: 10.1080/08869634.2021.1918959.
7. Pires PF, Castro EM, Pelai EB, de Arruda ABC, Bigaton DR. Analysis of the accuracy and reliability of the short-form Fonseca Anamnestic Index in the diagnosis of the myogenous temporomandibular disorder in women. Braz J Phys Ther. 2018; 22: 276-282.
8. Kheirabadi GR, Maracy MR, Akbaripour S, Masaeli N. Psychometric properties and diagnostic accuracy of the Edinburgh Postnatal Depression Scale in a sample of Iranian women. Iran J Med Sci. 2012; 37: 32-38.
9. Yazıcı E, Yazıcı AB. Gebelik ve postpartum döneminde psikiyatrik bozukluklar klinik ve tedavi başvuru kitabı. Bölüm adı: Postpartum depresyon Editör: Prof. Dr. Faruk Uğuz. Birinci basım, 2017; sfy 31-49. Vizyon basımevi, İstanbul, Türkiye
10. Lobbezoo F., Ahlberg J., Glaros A.G., Kato T., Koyano K., Lavigne G.J., de Leeuw R., Manfredini D., Svensson P., Winocur E. Bruxism defined and graded: an international consensus. Journal of Oral Rehabilitation 2013; 40(1): 2-4.
11. Paesani D.A., Lobbezoo F., Gelos C., Guarda-Nardini L., Ahlberg J., Manfredini D. Correlation between self-reported and clinically based diagnoses of bruxism in temporomandibular disorders patients. Journal of Oral Rehabilitation 2013 DOI: 10.1111/joor.12101.
12. Zimmerman M., Aloia M. Sleep-disordered breathing and cognition in older adults. Curr Neurol Neurosci Rep 2012; 12: 537-546.
13. Tahrani A., Somers V., Caples S. Obstructive sleep apnea, cardiovascular disease, and diabetes. Curr Opin Pulm Med 2013; 19: 631-638.
14. LeResche L., Saunders K., Von Korff MR., Barlow W., Dworkin S.F. Use of exogenous hormones and risk of temporomandibular disorder pain. Pain 1997; 69: 153-160.
15. Young T., Peppard P.E., Taheri S. Excess weight and sleep-disordered breathing. J Appl Physiol 2005; 99: 1592-1599.
16. Veiga D.M., Cunali R., Bonotto D., Cunali P.A. Sleep quality in patients with temporomandibular disorder: a systematic review. Sleep Science 2013; 6(3): 120-124.
17. Zwiri A.M.A., Ghani Z.A., Husein A., Phaik K.S., Kassim N.K., Zainal S.A., Samsudin A.R. Obstructive sleep apnea and its relation with temporomandibular disorders: a narrative review. Journal of International Oral Health 2020; 12: 8-14.
18. Pires PF, Castro EM, Pelai EB, de Arruda ABC, Bigaton DR. Analysis of the accuracy and reliability of the short-form Fonseca Anamnestic Index in the diagnosis of the myogenous temporomandibular disorder in women. Braz J Phys Ther. 2018; 22: 276-282.
19. dos Santos Berni KC, Dibai-Filho AB, Rodrigues-Bigaton D. Accuracy of the Fonseca anamnestic index in the identification of myogenous temporomandibular disorder in female community cases. J Bodywork & Movement Therapies. 2015; 19(3): 405-409.
20. Smith M.T., Wickwire E.M., Grace E.G., Edwards R.R., Buenaver L.F., Peterson S., Klick B., Haythornthwaite J.A. Sleep disorders and their association with laboratory pain sensitivity in temporomandibular joint disorder. Sleep 2009; 32(6): 779-790.
21. Edwards R.R., Grace E., Peterson S., Klick B., Haythornthwaite J.A., Smith M.T. Sleep continuity and architecture: associations with pain-inhibitory processes in patients with temporomandibular joint disorder. Eur J Pain 2009; 13(10): 1043-1047.

22. Sanders A.E., Essick G.K., Fillingim R., Knott C., Ohrbach R., greenspan J.D., Diatchenko L., Maixner W., Dubner R., Bair E., Miller W.E., Slade G.D. Sleep apnea symptoms and risk of temporomandibular disorder: OPPERA cohort JDR Clin Res Supp 2013; 92(1): 70-77.
23. Cunali P.A., Almeida F.R., Santos C.D., Valdrighi N.Y., Nascimento N.S., Dal'Fabbro C., Tufik S., Bittencourt L., R., A. Prevalence of temporomandibular disorders in obstructive sleep apnea patients referred for oral appliance therapy. J orofac pain 2009; 23: 339-344.
24. Jokubauskas J., Baltrusaityte A. Relationship between obstructive sleep apnoea syndrome and sleep bruxism: a systematic review. Journal of Oral Rehabilitation 2017; 44: 144-153.
25. Saito M., Yamaguchi T., Mikami S., Watanabe K., Gotouda A., Okada K., Hishikawa R., Shibuya E., Lavigne G. Temporal association between sleep apnea-hypopnea and sleep bruxism events. J Sleep Res 2013; 23: 196-203.



EurAsian Journal of Oral and Maxillofacial Surgery

Official publication of AÇBİD
(Association of Oral and Maxillofacial Surgery Society)



CASE REPORT

Patient-Fitted Total Temporomandibular Joint Prosthesis: A Case Series

Seçil ÇUBUK, DDS, PhD, Palin ÇİFTÇİOĞLU, DDS, Burak BAYRAM, DDS, PhD,

Oral and Maxillofacial Surgery, School of Dentistry, Baskent University, Ankara, Turkey

Abstract

The treatment protocol of patients having end-stage temporomandibular joint (TMJ) disorder using patient-fitted TMJ prosthesis is presented in this case series. The prosthetic fossa and ramus components and the surgical guides were designed on the basis of the final position of the maxilla-mandibular skeleton using Geomagic software (Morrisville, North Carolina, USA). The prosthetic ramus component and the supporting frame of the fossa were produced using a titanium alloy. The fossa component was constructed solely from ultra-high molecular weight polyethylene. Patient-fitted TMJ prosthesis was placed through high submandibular and pre-auricular approach in 3 patients. No complication related to the operations was seen. Temporomandibular joint reconstruction using patient-fitted TMJ prosthesis resulted in satisfying jaw function and skeletal relationships in patients having end-stage TMJ disorder.

Keywords: temporomandibular joint; custom made prosthesis; end-stage disease

Introduction

End-stage temporomandibular joint (TMJ) diseases can result in severe functional and cosmetic impairments. Fortunately, it is possible to reconstruct the destroyed TMJ architecture using autogenous tissue grafts or a TMJ prosthesis. However, some TMJ diseases, for example, autoimmune diseases, may adversely affect the viability of autogenous tissue grafts. Thus, a TMJ prosthesis is considered to be the most favourable treatment option for patients with such diseases.

A patient-fitted TMJ prosthesis offers an optimal anatomical fit, good anchorage and comparable biomechanical consistency. Moreover, according to the results of several long-term studies, the examined patient-fitted TMJ prostheses functioned well and were associated with only a low incidence of adverse events.^{1,2}

This case series presents the treatment protocol followed for three cases whose end-stage TMJ diseases were managed using custom-made TMJ prostheses.

Case Series

Virtual surgical planning and manufacturing of devices

Cone-beam computed tomography (CBCT) images of each patient's craniomaxillofacial skeleton (0.75–1.25 mm slice spacing, 0.3–0.45 mm pixel size) were taken with the teeth in normal occlusion. A digital impression was acquired by scanning a previously obtained dental impression using an extraoral laboratory scanner. The DICOM (Digital Imaging and

Communications in Medicine) data were segmented using OsiriX MD software (Pixmeo SARL, Geneva, Switzerland) in order to produce a virtual three-dimensional (3D) model. The scanned dental arches were aligned and a 3D cephalometric analysis performed. Osteotomies were then created on the virtual model. The prosthetic fossa and ramus components and the surgical guides were designed on the basis of the final position of the maxilla-mandibular skeleton using Geomagic software (Morrisville, North Carolina, USA). The manufacturing of all the TMJ prostheses and the surgical guides was initiated after the surgeon had approved the project. The prosthetic ramus component and the supporting frame of the fossa were produced using a titanium alloy. The fossa component was constructed solely from ultra-high molecular weight polyethylene (UHMWPE) (Fig. 1). The devices were then delivered to the hospital and stored prior to surgical placement.

Surgical technique

All the surgeries were performed under general anaesthesia. A single dose of antibiotic (2 g cephapirin sodium) was administered intravenously. The TMJ prosthesis was inserted through high submandibular and pre-auricular approach. A coronoidectomy was performed to release the temporalis muscle. An abdominally harvested fat graft was placed around the prosthesis. All the patients were discharged on the third postoperative day.

Corresponding Author: Palin ÇİFTÇİOĞLU

Address: Department of Oral and Maxillofacial Surgery, Baskent Universitesi, Dis Hekimligi Fakultesi
82. Sok. No:26, Bahcelievler 06490 Ankara, Turkey.

Mobile: +90(312) 215 13 36

E-mail: pciftcioglu@hotmail.com

Case 1

A 20-year-old female patient was referred to our clinic with a complaint of severe facial asymmetry. The patient's medical history revealed that she had experienced TMJ ankylosis following the malunion of a unilateral condylar fracture. A costochondral graft had been placed by another clinic in an effort to correct the facial asymmetry; however, that treatment had failed and the re-ankylosis of the joint had occurred.

The patient's maximal mouth opening (MMO) was measured as 22 mm preoperatively. Initially, orthodontic treatment was performed to achieve the alignment and decompensation of the teeth. The patient underwent a mandible-first surgical procedure. More specifically, the left TMJ was reconstructed using a patient-fitted total TMJ prosthesis. Next, sagittal split ramus osteotomy was performed on the right side in order to reposition the mandible. The patient's maxillary asymmetry was corrected by means of Le Fort I osteotomy. Her facial aesthetics were significantly improved following the procedure, although mild asymmetry remained (Fig. 1). The improvements noted in parameters such as the patient's MMO (30 mm), jaw function and TMJ pain were maintained at the end of the one-year follow-up period.

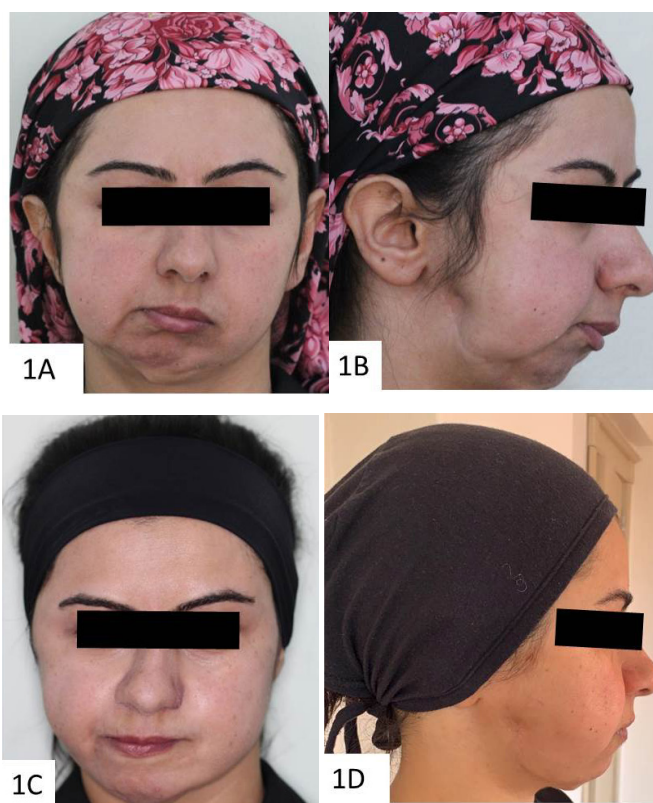

Figure 1:(A) Frontal view of the patient before surgery. (B) Facial profile of the patient before surgery. (C)Frontal view of the patient after surgery. (D)Facial profile of the patient after surgery.

Case 2

A 39-year-old female patient who had previously undergone marsupialisation to remove keratocysts was referred to our clinic with a complaint of swelling on her left mandible. A recurrent lesion, which involved the ascending ramus and coronoid process, was observed on the patient's CBCT imaging results.

The lesion was enucleated and coronoidectomy was performed as the first intervention at our clinic. However, the recurrence of the lesion was noted during the three-year follow-up session. Therefore, resection of the left ramus mandible and reconstruction using a total TMJ prosthesis were performed. No pain or signs of infection were observed at the end of the six-month follow-up period after this second intervention (Fig. 2).

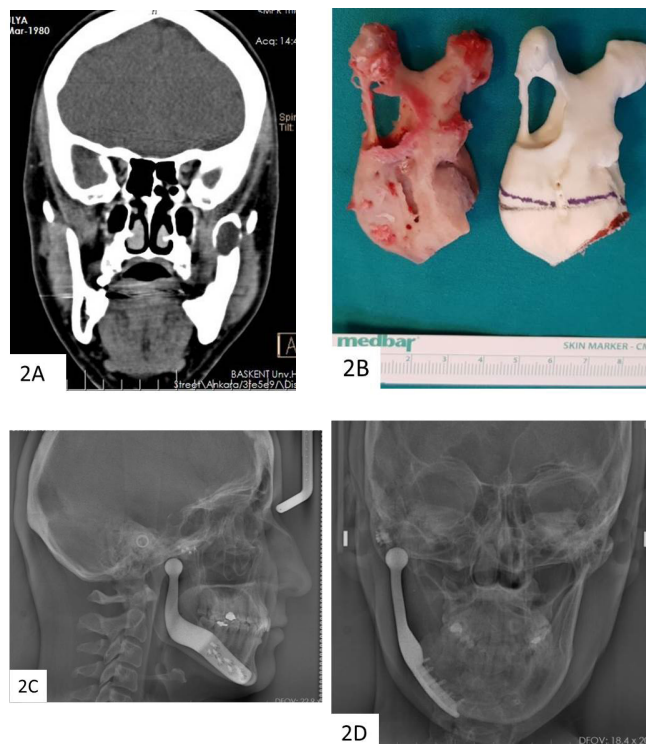


Figure 2:(A) CT imaging of the patient having recurrent keratocysts.(B) Resection of condyle and ramus was performed in accordance with the 3D surgical planning. (C) Lateral cephalometric radiograph of the patient after surgery. (D) Anteroposterior radiograph of the patient after surgery.

Case 3

A 32-year-old female patient was referred to our clinic with a complaint of severe mandibular retrusion. She presented with oligoarticular juvenile idiopathic arthritis (JIA). Moreover, her CBCT imaging results revealed class II skeletal deformity and flattened bilateral condylar heads.

The patient began orthodontic treatment in preparation for the surgery. Her MMO was recorded as 34 mm preoperatively. Mandibular advancement was achieved by means of TMJ reconstruction using a TMJ prosthesis. Six months after the first intervention, genioplasty was also performed. The

patient's postoperative MMO was measured as 34 mm. In addition, a balanced facial profile was obtained (Fig. 3).

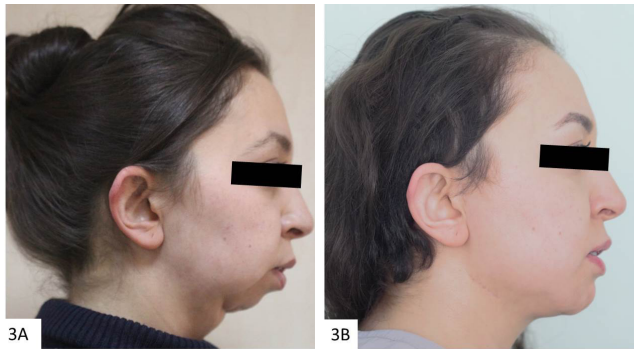


Figure 3:(A) Facial profile of the patient before surgery. (B) Facial profile of the patient after surgery.

Discussion

Alloplastic TMJ prostheses can be used for the treatment of various TMJ conditions, including congenital disorders of the TMJ, degenerative joint diseases, ankylosis and failed TMJ surgeries. Patients who have received custom-made prostheses report less TMJ pain, improved jaw function, increased ability to eat solid food and improved quality of life at the 20-year follow-up point.²

Unilateral condylar injury during childhood may cause both functional disorders and facial asymmetry. Superior impaction of the fractured condylar neck usually occurs when the displaced condylar head is not properly returned to its original position, which results in the shortening of the ramus. The use of a costochondral graft for TMJ replacement is generally accepted as the ideal treatment method in children.³ However, a number of complications, such as pneumothorax, ankylosis and the overgrowth of the graft, may develop.^{4,5} In addition, a previous study reported that the resorption of the costochondral graft occurred in 25% of patients.⁴ The post-traumatic TMJ deformity of the patient referred to as Case 1 in the present case series was reconstructed using a costochondral graft during childhood. However, the graft developed an undergrowth, which meant that severe facial asymmetry could still be observed in the patient. A patient-fitted TMJ prosthesis was chosen as the treatment method for correcting the facial asymmetry seen in this patient, as such an approach is known to be associated with more predictable results in patients who have undergone multiple surgeries.² In fact, the facial asymmetry was substantially corrected in this patient, while the outcomes remained stable during the four-year follow-up period.

Patients with JIA may exhibit TMJ involvement, which can result in dentofacial deformities. Both solely orthognathic surgery and orthognathic surgery concurrent with TMJ replacement can be considered viable treatment methods depending on the severity of the deformity. Prior studies have indicated that the immunosuppressant therapies used for the treatment of JIA may increase the risk of developing an infection following the placement of the prosthesis.^{6,7} However, the actual influence of immunosuppressant therapies on the development of infection after the placement of a TMJ prosthesis remains unclear. No signs of infection were seen in the patient with JIR (i.e. Case 3) featured in this case series.

As a conclusion, patient-fitted TMJ prosthesis allowed for large and extremely stable mandibular advancements and substantial increase in posterior facial height to obtain facial symmetry and balanced facial profile.

References

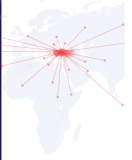1. Aagaard, E., & Thygesen, T. (2014). A prospective, single-centre study on patient outcomes following temporomandibular joint replacement using a custom-made Biomet TMJ prosthesis. *International journal of oral and maxillofacial surgery*, 43(10), 1229-1235.
2. Wolford, L. M., Mercuri, L. G., Schneiderman, E. D., Movahed, R., & Allen, W. (2015). Twenty-year follow-up study on a patient-fitted temporomandibular joint prosthesis: the Techmedica/TMJ Concepts device. *Journal of Oral and Maxillofacial Surgery*, 73(5), 952-960.
3. Lee, W. Y., Park, Y. W., & Kim, S. G. (2014). Comparison of costochondral graft and customized total joint reconstruction for treatments of temporomandibular joint replacement. *Maxillofacial plastic and reconstructive surgery*, 36(4), 135.
4. Medra, A. M. (2005). Follow up of mandibular costochondral grafts after release of ankylosis of the temporomandibular joints. *British Journal of Oral and Maxillofacial Surgery*, 43(2), 118-122.
5. Villanueva Alcojol, L., Monje Gil, F., González García, R., Moreno García, C., Serrano Gil, H., Maestre Rodríguez, O., ... & Mateo Arias, J. (2009). Costochondral graft with green-stick fracture used in reconstruction of the mandibular condyle: experience in 13 clinical cases.
6. McLean-Tookey, A., Aldridge, C., Waugh, S., Spickett, G. P., & Kay, L. (2009). Methotrexate, rheumatoid arthritis and infection risk-what is the evidence?. *Rheumatology*, 48(8), 867-871.
7. Scherrer, C. B., Mannion, A. F., Kyburz, D., Vogt, M., & Kramers-de Quervain, I. A. (2013). Infection risk after orthopedic surgery in patients with inflammatory rheumatic diseases treated with immunosuppressive drugs. *Arthritis care & research*, 65(12), 2032-2040.



EurAsian Journal of Oral and Maxillofacial Surgery

Official publication of AÇBİD
(Association of Oral and Maxillofacial Surgery Society)

EurAsian Journal of
Oral and Maxillofacial Surgery



CASE REPORT

Conservative Management of Large Dentigerous Cysts in Children

Ayşe OZCAN KUCUK, DDs,MDs¹, Mahmut KOPARAL, DDs,PhD², Aydın KESKINRUZGAR, DDs,PhD²,

¹Department of Oral and Maxillofacial Surgery, Faculty of Dentistry, Mersin University, Mersin, Turkey

²Department of Oral and Maxillofacial Surgery, Faculty of Dentistry, Adiyaman University, Adiyaman, Turkey

Abstract

Objective: Dentigerous cysts are benign odontogenic cysts which are associated with the crowns of permanent teeth and rarely seen during childhood. In most cases, they are painless and asymptomatic and usually can be detected by routine radiographs. For treatment of dentigerous cysts, the principal surgical methods are enucleation and decompression. The aim of this presentation is to share our experiences in a case series of children with the dentigerous cysts treated by decompression to allow the eruption.

Cases: Dentigerous cysts enclosing the crown of an unerupted/impacted tooth of 4 children aged 7-11 years were treated with decompression with a tube drain. The results of clinical examination, radiologic findings and the treatment of the cysts were presented.

Conclusion: Decompression therapy, which aims to eliminate the cystic tissue and protect the permanent teeth in the dentigerous cyst, is very effective in the management of dentigerous cysts during mixed dentition in the childhood.

Keywords: Decompression, Dentigerous cyst, Children, Conservative

Introduction

Dentigerous cyst (DC) is the second-most common type of odontogenic cyst associated with unerupted/impacted teeth.^{1,2} The modalities for treating DCs usually consist of surgical techniques such as marsupialization/decompression and enucleation.³

The aim of this study is to present a case series of children with the DCs successfully treated by tube decompression.

Cases

Case 1: A 9-year-old boy referred to our clinic with a chief complaint of swelling over the left cheek. Intraoral examination revealed a swelling on the lower left vestibule. The panoramic radiography (OPG) revealed a well-defined unilocular radiolucency circumscribing the germs of the first and second premolar on the mandibular left side (Figure 1). The mandibular left first and second primary molar were extracted and a silicon tube was placed through the opening (Figure 2). The drain was irrigated using normal saline 3 times a day for 3 months (Figure 3).

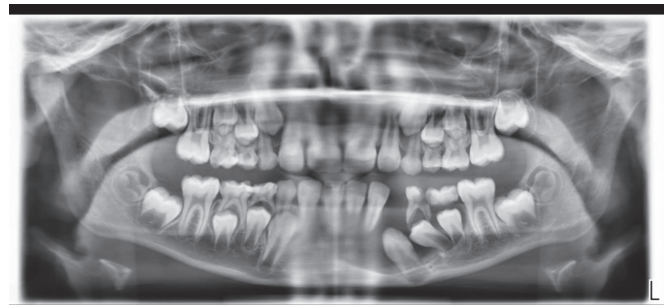


Figure 1. Preoperative panoramic radiograph showing the large dentigerous cyst and displaced teeth.

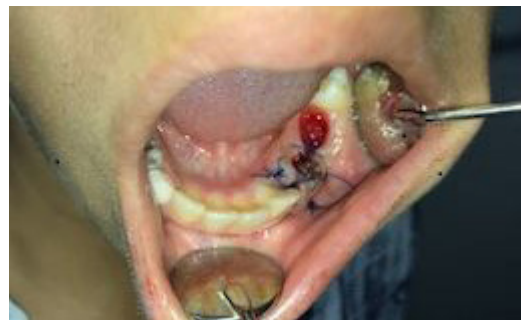

Figure 2. Clinical aspect immediately after decompression

Corresponding Author: Ayşe OZCAN KUCUK

DDs, MDs, Ass. Prof.

Address: Department of Oral and Maxillofacial Surgery, Faculty of Dentistry, Mersin University, Yenişehir/Mersin

Mobile: +90(539) 859 34 61

e-mail: ayseozcan89@hotmail.com

of the dentigerous cyst, showing a silicone tube made of anesthetic cartridges installed in the cystic cavity.

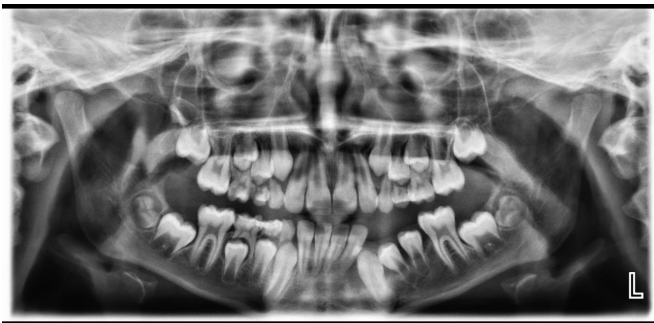

Figure 3. Panoramic radiograph of the case taken at the 4 months after decompression

Case 2: A 7-year-old boy was referred to our clinic for treatment of a lesion in the right lower jaw detected through routine OPG. An intraoral examination revealed an expansion in the region of the mandibular right first primary molar. The OPG showed a well-defined unilocular radiolucency circumscribing the impacted mandibular right first molar. The mandibular right second primary molar was extracted and a silicon tube was inserted through the opening. The drain was irrigated 3 times a day for 3 months.

Case 3: A 10-year-old boy was referred to our clinic with a complaint of pain in the mandible. At intraoral examination, carious lesions were observed in the mandibular right second primary molar and permanent first molar. The OPG showed a well-defined osteolytic lesion circumscribing the unerupted second premolar in mandible. The mandibular right second primary molar was extracted and a silicon tube was inserted through the opening. The drain was irrigated 3 times a day for 5 months.

Case 4: A 11-year-old boy was referred to our clinic for treatment of a lesion detected through routine OPG. Carious lesion was observed in the mandibular right second primary molar in the intraoral examination. Radiographic examination showed a well-defined unilocular radiolucent area circumscribing the unerupted second premolar in mandible. The mandibular right second primary molar was extracted and decompression was performed using a silicone tube. The drain was irrigated 3 times a day for 2 months.

Discussion

Different surgical treatment procedures have been applied to treat DCs. Among them, the conservative treatments such as decompression and marsupialization are very important for the cases of large lesions of jaws and when the permanent teeth involved have eruptive potential.²⁻⁵ These two terms were used interchangeably in some articles. However, they have different technical meanings. Decompression implies any means taken to reduce the intracystic pressure. Marsupialization means the conversion of the cyst into a pouch. Therefore, marsupialization means decompressing a cyst.⁶

Paediatric patients have a great regenerative potential and teeth with incomplete root development maintain the eruptive strength. Therefore, decompression is very effective in the

management of DCs during mixed dentition in the children.⁷ When compared with enucleation, this approach minimizes the risk for complications such as loss of tooth germs and facial bone structures and injuries to blood vessels and nerves. However, follow-up care was required during this treatment period.⁸ The children reported in this paper were treated only with decompression to preserve the affected teeth. Between 3 and 8-months follow-up visits, a complete reduction in radiolucency with spontaneous eruption of the tooth was revealed in all patients.

In conclusion, decompression should be tried as a major therapy for DCs in children to preserve and promote the eruption of permanent teeth.

References

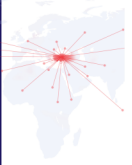1. Daley TD, Wysocki GP, Pringle GA. Relative incidence of odontogenic tumors and oral and jaw cysts in a Canadian population. *Oral Surg Oral Med Oral Pathol.* 1994;77(3):276-80.
2. Bodner L, Woldenberg Y, Bar-Ziv J. Radiographic features of large cystic lesions of the jaws in children. *Pediatr Radiol* 2003;33:3-6.
3. Hyomoto M, Kawakami M, Inoue M, Kirita T. Clinical conditions for eruption of maxillary canines and mandibular premolars associated with dentigerous cysts. *Am J Orthod Dentofac Orthop.* 2003;124:515-20.
4. Takagi S, Koyama S. Guided eruption of an impacted second premolar associated with a dentigerous cyst in the maxillary sinus of a 6-year-old child. *J Oral Maxillofac Surg.* 1998;56(2):237-9.
5. Arjona-Amo M, Serrera-Figallo MA, Hernández-Guisado JM, Gutiérrez-Pérez JL, Torres-Lagares D. Conservative management of dentigerous cysts in children. *J Clin Exp Dent.* 2015;7(5):e671-e674.
6. Pogrel MA. Decompression and marsupialization as a treatment for the odontogenic keratocyst. *Oral Maxillofac Surg Clin North Am.* 2003;15(3):415-27.
7. Carrera, Manoela, Dantas, Danilo Borges, Marchionni, Antônio Mareio, Oliveira, Marília Gerhardt de, & Andrade, Miguel Gustavo Setúbal. Conservative treatment of the dentigerous cyst: report of two cases. *Braz J Oral Sci* 2013;12(1):52-56.
8. Berdén J, Koch G, Ullbro C. Case series: Treatment of large dentigerous cysts in children. *Eur Arch Paediatr Dent.* 2010;11(3):140-5.



EurAsian Journal of Oral and Maxillofacial Surgery

Official publication of AÇBİD
(Association of Oral and Maxillofacial Surgery Society)

EurAsian Journal of
Oral and Maxillofacial Surgery



CASE REPORT

Mandible-first sequence approach in bimaxillary orthognathic surgery using 3D printed surgical templates for facial asymmetry

Cihan VAROL¹, Yavuz FINDIK¹, Timuçin BAYKUL¹, Gülperi KOÇER¹, Mehmet Fatih ŞENTÜRK¹, Tayfun YAZICI¹, Mustafa Yasin YETER²

¹Department of Oral and Maxillofacial Surgery, Suleyman Demirel University, Isparta, Turkey

²Private Dental Clinic, Eskişehir, Turkey

Abstract

Bimaxillary orthognathic surgery has been widely performed to achieve optimal functional and aesthetic outcomes in patients with maxillofacial deformity. Although Le Fort I osteotomy is generally performed before bilateral sagittal split osteotomy (BSSO) in the surgery, in several situations BSSO should be performed first.

The aim of this study to present the case of a 22 years old female patient with class III malocclusion and facial asymmetry. The desired movements were planned in 3D virtual planning on the computer with Nemofab software. Any complication was observed in the postoperative follow-up of the patient.

Conclusion: The maxillofacial deformities are treated with orthodontics and maxillofacial surgery co-operation. Traditional model surgery is generally used for surgical planning but computer aided virtual planning and printed surgical templates from 3D printers is a good alternative for surgical planning nowadays.

Keywords: Mandible-first, virtual planning, orthognathic surgery

Introduction

Dentofacial deformities are defined as hard and soft tissue abnormalities affecting jaws. The teeth located in the alveolar process of the affected bones will frequently present with malocclusion, crowding, dental compensations and rotations. Orthodontic treatment may be sufficient to manage mild dentoskeletal deformity, but as the magnitude and severity of the deformity increases, treatment with combined orthodontics and orthognathic surgery will be required.¹

Case Report

Twenty five years old female patient was consulted to our clinic with facial asymmetry. After the patient's clinical and radiological evaluation, the indication for bimaxillary surgery was determined. 3D planning was performed because it was difficult to perform with conventional model surgery. Virtual surgery was performed with Nemofab software (Nemotec, Spain).

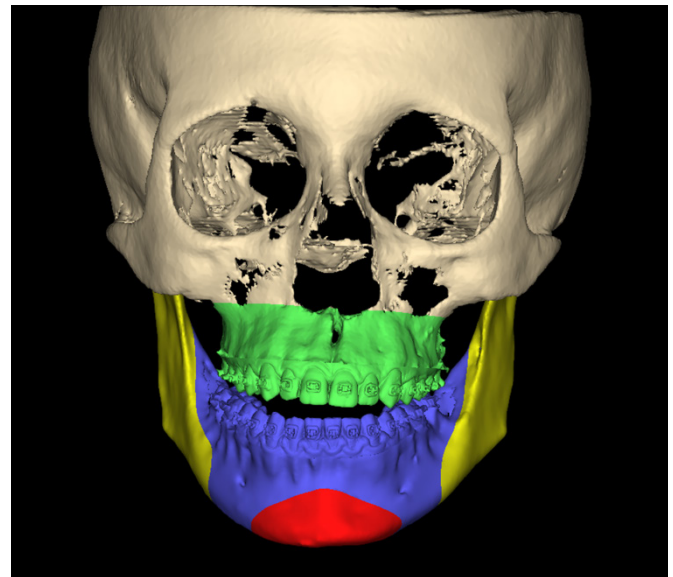


Fig.1:Pre-operative view.

Corresponding Author: Cihan VAROL

Research Assistant

Address: Süleyman Demirel University, Department of Oral and Maxillofacial Surgery, Çünür Mah. Merkez, Isparta, Turkey

Mobile: +90(505) 609 01 50

e-mail: cihanvarol.cv@gmail.com

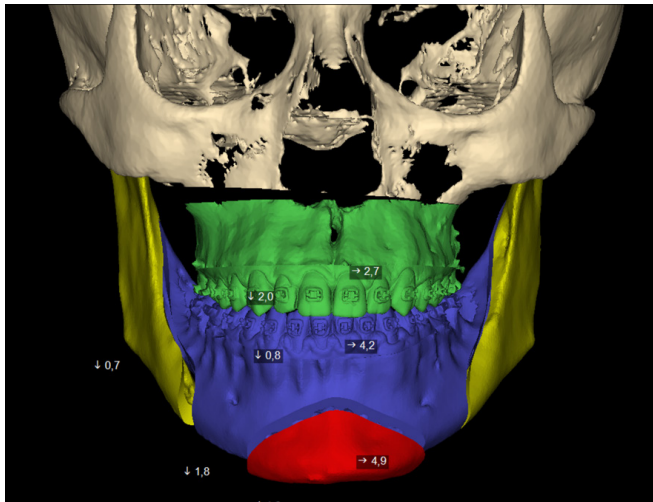


Fig.2: Segmental movement amounts after the completion of 3D planning.

Discussion

In relation to accuracy of orthognathic surgery, the traditional maxilla-first procedure offers variable but well-documented results with acceptable outcomes.² While the maxilla-first sequence is generally preferred, mandible-first would be favoured in situations such as counterclockwise rotation of the occlusal plane thus avoiding an intraoperative anterior open bite, inaccuracy of interocclusal records and uncertainty in precise condylar positioning, concomitant Temporomandibular joint surgery, or an expected difficulty in maxillary fixation as seen in segmental maxillary osteotomies.³ In our case, we chose the mandible first approach because we planned counterclockwise rotation of occlusal plane, virtual planning and 3D printed surgical templates were facilitated our operation.

Conclusion

With the rising popularity of virtual surgical planning, there has been increased interest in "mandible-first surgery". Traditional model surgery is generally used for surgical planning but computer aided virtual planning is a good alternative and facilitating factor for surgical planning nowadays. The literature on the mandible first provides little outcomes data, and its use is currently supported only by the opinion of authors and a single retrospective case series. While there appear to be significant theoretical advantages to support the use of the mandible-first approach, future prospective studies on its reliability, accuracy, short and long-term outcomes are required.

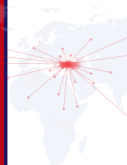References

1. Mandible-first sequence in bimaxillary orthognathic surgery: a systematic review A. M. Borba, A. H. Borges, B. A. Venturi, M. G. Nacrio-Homem, M. Miloro: Mandible-first sequence in bimaxillary orthognathic surgery: a systematic review. *Int. J. Oral Maxillofac. Surg.* 2016; 45: 472-475.
2. Gil JN, Claus JD, Manfro R, Lima Jr SM. Predictability of maxillary repositioning during bimaxillary surgery: accuracy of a new technique. *Int J Oral Maxillofac Surg* 2007;36:296-300.
3. Perez D, Ellis 3rd E. Sequencing bimaxillary surgery: mandible first. *J Oral Maxillofac Surg* 2011;69:2217-24.



EurAsian Journal of Oral and Maxillofacial Surgery

Official publication of AÇBİD
(Association of Oral and Maxillofacial Surgery Society)



CASE REPORT

Maxillary Midpalatal Sagittal Fracture: A Case Report

Çiğdem ÇETİN GENÇ, Assistant Professor,

Çanakkale Onsekiz Mart University, Faculty of Dentistry, Department of Oral and Maxillofacial Surgery, Çanakkale, Turkey

Abstract

Objective: In this paper, we aimed to present a case management with maxillary midpalatal and mandible fractures on clinical and radiological examination under the literature's knowledge.

Case: A traffic accident history patient, clinical and radiological examination revealed maxillary midpalatal and mandibular fractures. A closed reduction approach was deemed appropriate for the patient, and the fracture was reduced with intermaxillary fixation.

Conclusion: Palatal fractures are rarely seen in maxillofacial injuries. It can often be overlooked in facial traumas, cervical injuries, and sequelae are seen in untreated or incompletely treated cases. After diagnosing the fracture, it is essential to consider the fracture type and appropriate treatment methods.

Keywords: palatal fracture, management, median palatal fracture

Introduction

Maxillary hard palate fractures are rarely seen in the mandible, more often in the mid-face, panfacial, and rarely isolated.1 concomitant injuries, and management of palatal fractures at a level I trauma center in an urban environment. Methods: Data were collected for all palatal fractures diagnosed between January 2000 and December 2012 at the University Hospital in Newark, NJ. Data on patient demographics, Glasgow Coma Scale score on presentation, concomitant facial fractures, extrafacial injuries, and management strategies were collected from these records. Results: Of the 3147 facial fractures treated at our institution during this time period, 61 were associated with a palatal fracture following blunt trauma. There was a strong male predominance (87% Rene Le Fort described palatal fractures in 1901.2 It often occurs due to traffic accidents and high-speed impacts such as motorcycles accidents. Less is due to falling from a height, interpersonal violence, gunshot wound. Most of the patients are in the 20-40 age range and predominantly in men. They are rarely seen in children due to the flexibility of the facial bones and delayed closure of the palatal suture.1,3 concomitant injuries, and management of palatal fractures at a level I trauma center in an urban environment. Methods: Data were collected for all palatal fractures diagnosed between January 2000 and December 2012 at the University Hospital in Newark, NJ. Data on patient demographics, Glasgow Coma Scale score on presentation, concomitant facial fractures, extrafacial injuries, and management

strategies were collected from these records. Results: Of the 3147 facial fractures treated at our institution during this time period, 61 were associated with a palatal fracture following blunt trauma. There was a strong male predominance (87% Clinic symptoms are mobilization of fragments, unilateral or bilateral malocclusion in the vestibule-palatine direction, cleft palate-like clinical appearance, mucosal rupture around the fracture line, and ecchymosis, hematoma at the palatal vault.4

Case Report

A 25-year-old male patient treated for about 15 days in the intensive care unit due to a traffic accident was referred to our clinic to treat maxilla and mandible fractures after his general condition improved. In the clinical and radiological examination, unilateral malocclusion, mucosal rupture, and a cleft-like palatal gap at the palatal vault, and concomitant mandibular fracture have been observed. (Figure 1) Furthermore, it was diagnosed as a Midline Sagittal Palatal fracture according to Hendrickson's classification.

A closed reduction approach was deemed appropriate for the patient. The fracture was reduced and stabilized with intermaxillary fixation. Following the arch bar application, occlusion was provided with the guidance of elastics. (Figure 2) On the 5th day, occlusion was achieved, and the palatal gap was closed on a large scale. It was observed that the palatal gap was closed entirely 45 days after the operation. (Figure 3)

Corresponding Author: Çiğdem ÇETİN GENÇ
Assistant Professor

Address: Onsekiz Mart University, Faculty of Dentistry, Department of Oral and Maxillofacial Surgery, Cumhuriyet District Sahilyolu Street, No:5, Kepez, Çanakkale

Mobile: +90(538) 473 04 82

E-mail: cigdemcetingenc@comu.edu.tr

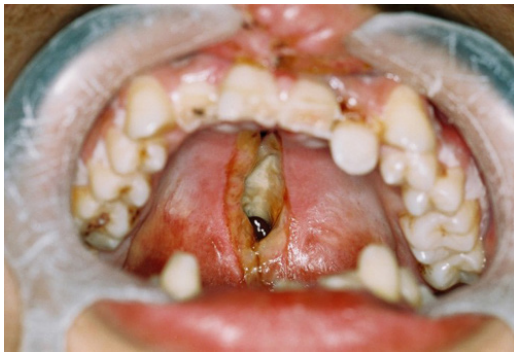

Figure 1: Palatal fracture line

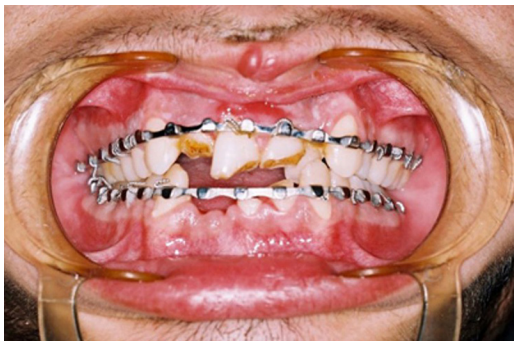

Figure 2: Occlusion after intermaxillary fixation.

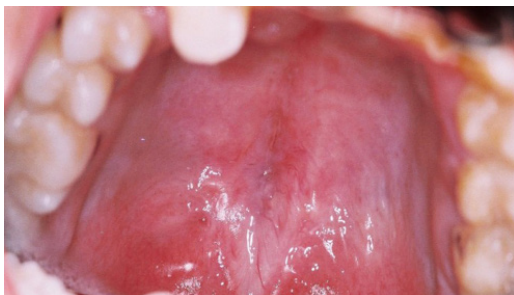

Figure 3: Postoperative healing of fracture site at 45th -day

Discussion

Palatal fractures are challenging to diagnose and treat due to the anatomical nature of the area. These fractures may go unnoticed due to traumatic brain injury and intraabdominal injuries, which are the most common accompanying injury at midline palate fractures. In addition, accompanying zygomatic, orbital, mandibular, orbital, and nasoorbitoethmoidal fractures make diagnosis challenging.^{1,5} concomitant injuries, and management of palatal fractures at a level I trauma center in an urban environment. Methods: Data were collected for all palatal fractures diagnosed between January 2000 and December 2012 at the University Hospital in Newark, NJ. Data on patient demographics, Glasgow Coma Scale score on presentation, concomitant facial fractures, extrafacial injuries, and management strategies were collected from these records. Results: Of the 3147 facial fractures treated at our institution during this time period, 61 were associated with a palatal fracture following blunt trauma. There was a strong male predominance [87%]

Various classifications of palatal fractures have been made over the years. Hendrickson et al. were classified the palatal

fracture according to the anatomy and location of the fracture with the patient's CT scans and divided the palatal fractures into six types; Anterior and Posterolateral Alveolar Fractures, Midline Sagittal Palatal, Parasagittal, Para-alveolar, Complex Fracture, and Transverse Palatal Fractures.⁴ Park et al. have classified the palate fracture according to the treatment method.⁶ Chen et al. has made a classification according to both anatomical and treatment method.⁵ 162 patients were diagnosed with palatal fractures. The classification of fractures was based on the patterns observed on computed tomographic scans and treatment plan including type I, sagittal; type II, transverse; and type III, comminuted. Transverse palatal fractures were stabilized by standard Le Fort I buttresses and alveolar ridge fixation. Additional intermolar wiring fixation was applied for sagittal palatal fractures, and prolonged intermaxillary fixation with dental splinting was applied for comminuted palatal fractures. Results: Palatal fractures accounted for 46.4 percent of Le Fort maxillary fractures in this study. Motorcycle accident (69.5 percent)

Many treatment methods have been described in the literature. Conventional treatment or open reduction can be considered depending on the type of fracture, whether the patient is dentulous or edentulous such as open reduction with rigid fixation, Erich arch bars, acrylic palatal splint, Kirshner-wire fixation, circumcuspid or circummolar wires, and circumdental, inter-fragmental wiring, transverse palatal, and horizontal mattress wire. All of them have advantages and disadvantages.^{1,3-5,7,8} concomitant injuries, and management of palatal fractures at a level I trauma center in an urban environment. Methods: Data were collected for all palatal fractures diagnosed between January 2000 and December 2012 at the University Hospital in Newark, NJ. Data on patient demographics, Glasgow Coma Scale score on presentation, concomitant facial fractures, extrafacial injuries, and management strategies were collected from these records. Results: Of the 3147 facial fractures treated at our institution during this time period, 61 were associated with a palatal fracture following blunt trauma. There was a strong male predominance [87%]

Conclusion

The palatal fracture in the body can be overlooked due to panfacial, cervical spine, or life-threatening traumas, and sequelae are seen in untreated or improperly treated cases. After diagnosing the palatal fracture, it is essential to consider the fracture type and appropriate treatment methods.

Source of Finance

There is no financial source

Conflict of Interest

There is no conflict of interest.

ORCID ID: 0000-0001-6745-3790

References

1. Hoppe IC, Halsey JN, Ciminello FS, Lee ES, Granick MS. A Single-Center Review of Palatal Fractures: Etiology, Patterns, Concomitant Injuries, and Management. *Eplasty*. 2017;14(17):180-188.
2. Le Fort R. Etude experimentale sur les fractures de la machoire superieure. *Rev Chir*. 1901;23:208. <http://ci.nii.ac.jp/naid/10016046255/en/>. Accessed April 30, 2021.
3. Gala Z, Halsey JN, Kapadia K, et al. Pediatric Palate Fractures: An Assessment of Patterns and Management at a Level 1 Trauma Center. *Craniomaxillofac Trauma Reconstr*. 2021;14(1):23-28. doi:10.1177/1943387520935013
4. Hendrickson M, Clark N, Manson PN, et al. Palatal fractures: Classification, patterns, and treatment with rigid internal fixation. *Plast Reconstr Surg*. 1998;101(2):319-332. doi:10.1097/00006534-199802000-00009
5. Chen CH, Wang TY, Tsay PK, et al. A 162-case review of palatal fracture: Management strategy from a 10-year experience. *Plast Reconstr Surg*. 2008;121(6):2065-2073. doi:10.1097/PRS.0b013e3181706edc
6. Park S, Ock JJ. A new classification of palatal fracture and an algorithm to establish a treatment plan. *Plast Reconstr Surg*. 2001;107(7):1669-1676. doi:10.1097/00006534-200106000-00005
7. Pedemonte C, Valenzuela K, González LE, Vargas I, Noguera A. Types of Intermaxillary Fixation and Their Interaction With Palatine Fracture Reduction. *J Oral Maxillofac Surg*. 2019;77(10):2083.e1-2083.e8. doi:10.1016/j.joms.2019.06.006
8. Moss WJ, Kedarisetty S, Jafari A, Schaerer DE, Husseman JW. A Review of Hard Palate Fracture Repair Techniques. *J Oral Maxillofac Surg*. 2016;74(2):328-336. doi:10.1016/j.joms.2015.09.027



EurAsian Journal of Oral and Maxillofacial Surgery

Official publication of AÇBİD
(Association of Oral and Maxillofacial Surgery Society)



CASE REPORT

Primary Intraosseous Squamous Cell Carcinoma Coexisting with a Radicular Cyst:

Case Report

Merve ARICI, Trainees Resident¹, Okan DURAN, Trainees Resident¹, Orçun TOPTAŞ, DDs, PhD², Çetin BORAN, Associate Professor³

¹Department of Oral and Maxillofacial Surgery, Faculty of Dentistry, Bolu Abant İzzet Baysal University, Bolu, Turkey

²Assistant professor of Oral and Maxillofacial Surgery, private practice

³Department of Pathology, Faculty of Medicine, Bolu Abant İzzet Baysal University, Bolu, Turkey

Abstract

The term primary intraosseous odontogenic carcinoma (PIOC) has been primarily used to describe a squamous cell carcinoma within the jaws arising either from a previous odontogenic cyst or de novo. Primary intraosseous squamous cell carcinoma (PIO SCC) is a rarely seen malignant lesion in the jaw where there is no relation with soft tissues like the oral mucosa. The incidence of carcinomas arising from odontogenic cysts is particularly uncommon.

Case Report: In this case report, an intraosseous squamous cell carcinoma arising from a radicular cyst in a 60-year-old male patient is presented.

Conclusion: This case report clearly shows the significance of the clinician's awareness of a malignant potential of odontogenic cystic lesions and the correct time management of the treatment protocol of those lesions.

Keywords: Squamous Cell Carcinoma, Radicular Cyst

Introduction

Carcinoma arising in the jawbone in the epithelial lining of odontogenic cysts is an extremely rare condition. A primary intraosseous squamous cell carcinoma (PIO SCC) is defined as "a squamous cell carcinoma (SCC) arising within the jawbones, which having no initial connection with the oral mucous membrane.[1]

Malignant change in the epithelial lining of odontogenic cysts is very rare, but these changes have been described in the literature. [2,3]

Case Report

A 60-year-old male patient came to the clinic with a complaint of pain in the right maxillary lateral incisor area. The patient had a history of smoking, 2 packets/day for 40–45 years. The patient is free of any systemic illness. On extraoral examination, persistent cutaneous fistula on his right alar nose was observed in the last 6 months. The regional lymphadenopathy was absent. On CBCT and panoramic radiographs, an oval, unilocular radiolucent lesion with sclerotic borders, similar to the radicular cyst associated with the upper right lateral incisor root, was detected (Figure1). After root canal treatment, it was decided to perform apical resection of the relevant tooth. Under

local anaesthesia, sulcular incision was made and the area was exposed clearly. Erosion of the buccal plate was observed intraoperatively. The apical resection was made and the cystic lesion around the tooth was enucleated from the maxillary bone. Excisional biopsy was done and sent for histopathological examination. Histopathological analysis showed a cystic lesion partially lined by nonkeratinized stratified squamous epithelium which was altered by the intense inflammatory cell and the tumour infiltration into the fibrous cystic tissue wall (Figure2). Degenerative changes and dysplastic features were observed in the epithelial lining of the cystic wall. The islands of anaplastic squamous cells with marked nuclear pleomorphism, hyperchromatism, and individual cell keratinisations were characterized in a connective tissue wall of cystic lesion (Figure3). Histopathological examination indicated that the lesion was PIO SCC originating from the Radicular cyst lining. The Radiation Oncology Department was consulted, and the treatment started. Due to their location within the bone, SCC arising from a radicular cyst is staged as T2 cancer. To achieve negative margins, frozen section examination was applied during surgery, and lesion margins with high dysplastic features, confirming the tumour size up to 3x2x2 cm, were determined. Including the 1 cm healthy bone margin, the maxillary bone was removed. The patients

Corresponding Author: Merve ARICI
Trainees Resident

Address: Department of Oral and Maxillofacial Surgery, Faculty of Dentistry, Bolu Abant İzzet Baysal University, Bolu, Turkey

Mobile: +90(536) 402 39 89

E-mail: dmdmerve@gmail.com

received adjuvant radiation therapy in addition to surgery. The postoperative course was uneventful except for scar formation and no recurrence was observed for 6 months following surgery.

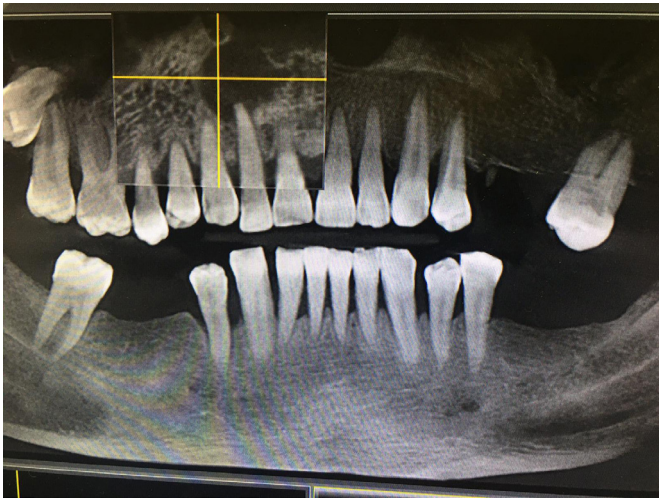


Figure 1: CT showing the periapical lesion at the root of the upper right lateral incisor

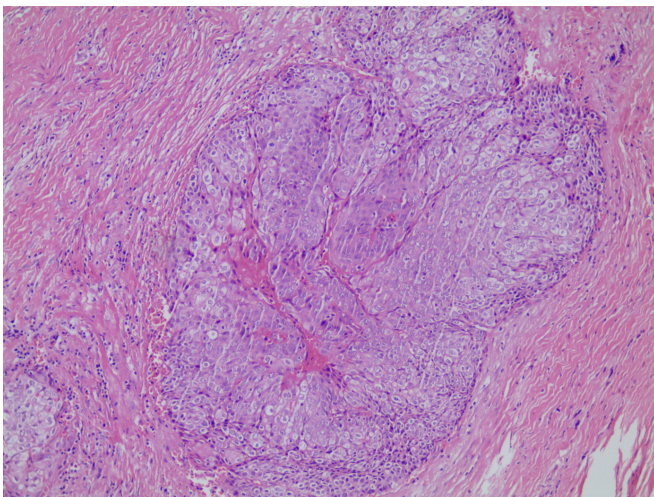


Figure 2: Tumour infiltration into the fibrous cystic tissue wall (HEx100)

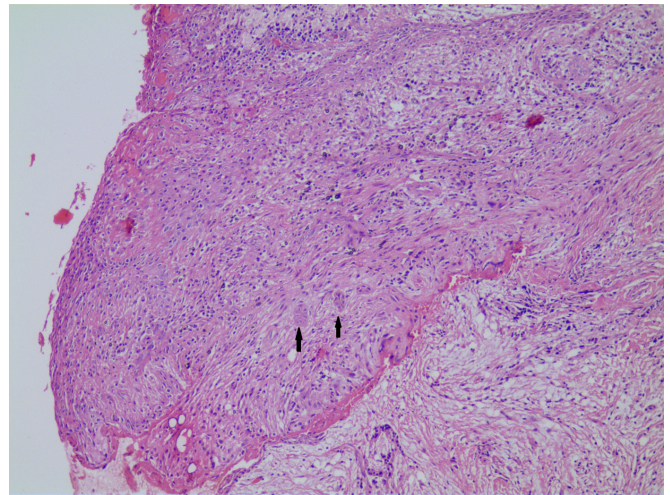


Figure 3: Dysplastic features with microinvasion seen as the island of anaplastic squamous cells with marked nuclear pleomorphism (Hex100)

Discussion:

The mean age of patients in PIOSCC and odontogenic cysts is 60.2 years. While it is more common in males, the estimated prevalence rate is 2/1 for males/females.[4] As in a similar previous report, PIOSCC originating from the radicular cyst was detected in this case.

PIOSCC ex odontogenic cysts represent well or moderately differentiated squamous cell carcinoma arising from the cystic epithelial lining [4,5]. In this study, the histopathological assessment showed a well-differentiated squamous carcinoma that developed from a radicular cyst.

In the patients with carcinoma in situ or located intramurally within the cyst, surgical removal is the choice treatment, and the patient should be followed up. Additional therapy such as bone resection, radiotherapy, and chemotherapy even neck dissection should be planned in the patients with positive margins of the tumour and involved surrounding bone [6].

This report showed the significance of the careful examination of the clinical, radiographical, and histopathological features in order not to overlook pathological tissue like SCC in our case.

Acknowledgement:

The case study report was written by trainee resident Merve ARICI. The author of this report would like to express deep thank to Deniz Yaman and Professor Cetin Boran of Pathology Department for his review and useful comments on the report. Thanks go to Deniz YAMAN and Orcun Toptas for their support during writing process.

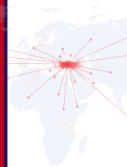Reference

1. Grisar K, Schol M, Hauben E, Schoenaers J, Politis C. Primary intraosseous squamous cell carcinoma of the mandible arising from an infected odontogenic cyst: A case report and review of the literature. *Oncol Lett*. 2016;12(6):5327-5331. doi:10.3892/ol.2016.5378
2. Kharazmi, M., Melville, J., Huang, A. et al. SCC from a dentigerous cyst. *Br Dent J* 229, 74 (2020). <https://doi.org/10.1038/s41415-020-1946-3>
3. Deihimy P, Karghahi N, Khalesi S. Squamous cell carcinoma arising in a radicular cyst: case report. *Int J Prev Med Res* 2015;1:22e6.
4. Gardner AF: A survey of odontogenic cysts and their relationship to squamous cell carcinoma. *Dent J* 1975;41:161- 7.
5. Kramer IRH, Pindborg JJ, Shear M. The WHO histological typing of odontogenic tumors. A commentary on the second edition. *Cancer* 1992; 70: 2988-94.
6. Bodner L, Manor E. Cystic lesions of the jaws – a review and analysis of 269 cases. *Eur J Plastic Surg* 2010; 33: 277–82.



EurAsian Journal of Oral and Maxillofacial Surgery

Official publication of AÇBİD
(Association of Oral and Maxillofacial Surgery Society)



CASE REPORT

Dentigerous Cyst Associated with Ectopic Canine of the Maxilla: A Case Report

Rıdvan GÜLER¹, Bekir İLYAS¹, Kamil Serkan AĞAÇAYAK¹

Dicle University, Faculty of Dentistry, Department of Oral and Maxillofacial Surgery, Diyarbakır, Turkey

Abstract

Dentigerous cysts (DC) are the second most common odontogenic cysts affecting the jaw bone that are associated with the crowns of permanent unerupted teeth; mostly single in occurrence and located in the mandible. DC is more usually seen with mandibular third molar and maxillary canine and seldom other teeth are involved. Dentigerous cysts remain asymptomatic and are generally diagnosed incidentally during the routine radiological examination. Enucleation is the standard treatment. In this report, large dentigerous cyst associated with the ectopic canine of the maxilla are presented.

Keywords: Dentigerous cyst, Maxillary, Odontogenic cyst, Enucleation

Introduction

Dentigerous cyst (DC), also known as follicular cyst, is the second most common form of odontogenic cysts after radicular cyst 1. The cystic lining is derived from the epithelial remnants of tooth forming organ. 2 Information on the prevalence of this disease is restricted. It is more common among males, and usually occurs in the second and third decade of life. Other common locations of DC are the third molar teeth of the maxilla, the maxillary canines, supernumerary teeth and the premolars of both jawbones.3

Dentigerous cysts are usually asymptomatic and found incidentally during the evaluation of an unerupted tooth.4 If the patient has infection and expansion, they become symptomatic. In the event of infection, it can cause a painful swelling. In the case of an expansion into cortical plates, DC can cause facial asymmetry, and destruction of the adjacent tissues. Histological diagnosis plays a key role in the definite diagnosis.

Those teeth located in the jawbones or in regions other than the alveolar arch are said to be ectopically placed. This may be due to irregularity in the migration of a tooth bud which occurs due to genetic relationship factors causing a budding tooth to congenitally migrate in the initial stages of embryogenesis, or is the result of displacement of the teeth owing to local factors.5 There are many treatment options of dentigerous cyst. These are enucleation, marsupialization and decompression. These patient proper treatment is enucleation of the cyst and removal of the unerupted tooth. When complete excision of the cyst is achieved, the prognosis is nice and the recurrence rate is low.

Case Report

A 30-year-old female patient suffering from swelling of the right maxillary canine region with pain was referred to our department. She was systemically healthy and extra-oral examination was within normal limits. Her mouth opening was normal. On an intra-oral examination, we noted that the maxillary left canine were clinically unerupted. Clinical examination revealed an extraoral swelling on the left side of the face with elevation of the nostril and lateral border of the nose. There was obliteration of the nasolabial sulcus. Panoramic radiograph showed a well defined unilocular radiolucency surrounding canine teeth in the left premolar region of the maxilla. Displacement of the root of the maxillary left lateral teeth was also seen. (Fig.1)

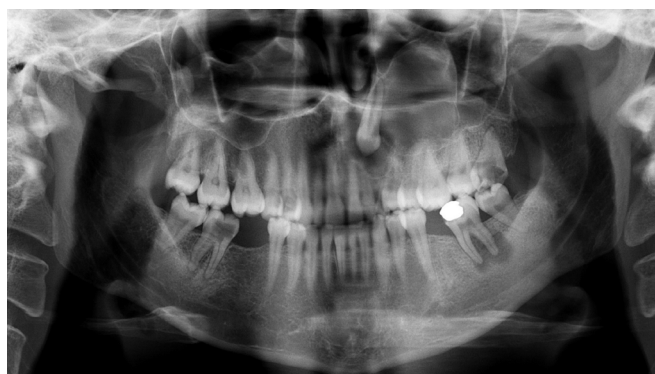

Figure 1 : Preoperative orthopantomograph

Corresponding Author: Rıdvan GÜLER

Research assistant

Address: Dicle University Faculty of Dentistry, Oral and Maxillofacial Surgery, Diyarbakır/Turkey

Mobile: +90(534) 764 49 21

E-mail: ridvanguler06@gmail.com

The diagnosis of dentigerous cyst was confirmed with clinic, radiographic and histopathologic findings. Dentigerous cyst histopathology shows a thicker epithelium lining with hyperplastic rete ridges. The fibrous cyst capsule showed a diffuse chronic inflammatory infiltrate. (Fig.3) DC was enucleated and the associated impacted teeth extracted under local anesthesia. The patient tolerated the procedure well. Sutures were removed on the eight day after operation and the postoperative course was uneventful. Post-operative clinical follow-up that was conducted after one and six month of the surgery was uneventful. (Fig.2)

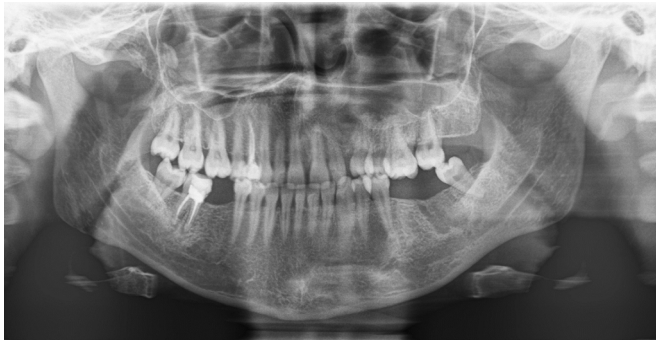

Figure 2 : Postoperative orthopantomograph (6 month)

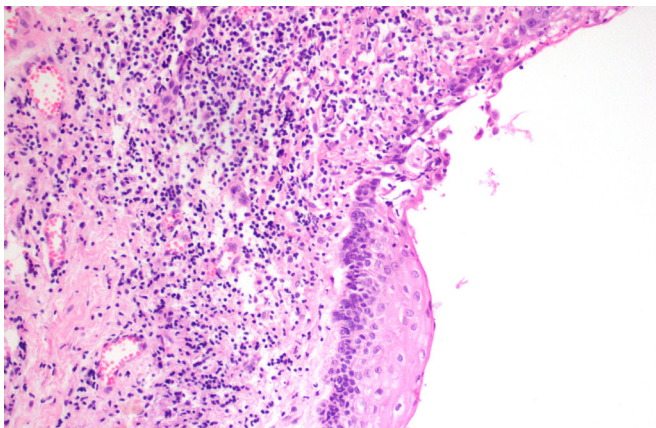


Figure 3 : Histopathologic view of the lesion. (H&E, X200)

Discussion

A dentigerous cyst is a cyst which generally encloses the crown of an unerupted tooth, expands the follicle, and is attached to the cemento-enamel junction of the tooth. DC are commonly seen in mandibular third molars, maxillary canines, and mandibular premolars, and they infrequently involve deciduous teeth.⁶ The incidence of DCs is 14%–20%. The exact histogenesis of DC is unclear, but some histopathological pathways have been described. DC attaches itself to the neck of the tooth and encloses the impacted tooth. The pressure applied by the emerging tooth on the dental sac blocks the venous outflow, causing the serum to rapidly pass through capillary walls. This accumulated fluid exerts an increasing hydrostatic pressure and detaches the dental arc from the crown of the tooth. The enlargement of the DC is associated with the proliferation of the epithelial cells and the osmolality of the fluid within the cyst.⁷ These cysts are lined by

nonkeratinized stratified squamous epithelium.

Radiographically, DC are suspected when the size of the follicular space is larger than 5 mm. Panoramic radiograph and upper occlusal radiograph are recommended as first-line diagnostic tools and further evaluation of the lesion by computed tomography examination.⁵ Radiographic examination showed as a unilocular radiolucency with a well-defined sclerotic border engulfing the crown of an impacted tooth.⁸

The differential diagnosis of DC includes ameloblastoma, odontogenic keratocyst, odontogenic fibroma, odontogenic myxoma, cementomas and Pindborg tumor. The treatment of DC is enucleation of the cysts and removal of the impacted or unerupted tooth. Large cysts like these can be marsupialized initially to decompress the cystic contents and enucleated more conservatively.⁶

Conclusion

Dentigerous cysts may cause symptom free large bone defects. It is therefore important to perform radiographic examination of all unerupted teeth.

References

1. Guruprasad Y, Chauhan DS, Kura U. Infected dentigerous cyst of maxillary sinus arising from an ectopic third molar. *J Clin Imaging Sci.* 2013;3:7. doi: 10.4103/2156-7514.117461.
2. Amin ZA, Amran M, Khairudin A. Removal of extensive maxillary dentigerous cyst via a Caldwell-Luc procedure. *Arch Otorhinolaryngol.* 2008;3:48–51.
3. Bonardi JP, Gomes-Ferreira PH, de Freitas Silva L, Momesso GA, de Oliveira D, Ferreira S, et al. Large dentigerous cyst associated to maxillary canine. *J Craniofac Surg.* 2017;28:e96–e97. doi: 10.1097/SCS.0000000000003281.
4. Vasiappan H, Christopher PJ, Kengasubbiah S, Shenoy V, Kumar S, Paranthaman A. Bilateral Dentigerous Cyst in Impacted Mandibular Third Molars: A Case Report. *Cureus.* 2018 Dec 5;10(12):e3691. doi: 10.7759/cureus.3691.
5. Ramakrishna A, Lambade P. Dentigerous cyst associated with ectopic canine and a supernumerary tooth: a rare occurrence. *J Surg Tech Case Rep.* 2013;5(2):85–88. doi:10.4103/2006-8808.128738.
6. Vasiappan H, Christopher P J, Kengasubbiah S, et al. (December 05, 2018) Bilateral Dentigerous Cyst in Impacted Mandibular Third Molars: A Case Report. *Cureus* 10(12): e3691. DOI 10.7759/cureus.3691
7. Önay Ö, Süslü AE, Yılmaz T. Huge Dentigerous Cyst in the Maxillary Sinus: A Rare Case in Childhood. *Turk Arch Otorhinolaryngol.* 2019;57(1):54–56. doi:10.5152/tao.2019.1920
8. Ngamdu YB, Kodiya AM, Sandabe MB, Garandawa HI, Isa A. Dentigerous cyst associated with ectopic supernumerary canine in the maxillary sinus. *J C R.* 2012;2:27–30.



EurAsian Journal of Oral and Maxillofacial Surgery

Official publication of AÇBİD
(Association of Oral and Maxillofacial Surgery Society)



CASE REPORT

Diagnostic Handicap: RHABDOMYOSARCOMA

**Tolga BAYAR, DDS¹, Ebru Deniz KARSLI, PhD, DDS¹, Betül TAŞ ÖZYURTSEVEN, PhD, DDS¹,
Metin GÜNGÖRMÜŞ, PhD, DDS¹**

Gaziantep University, Faculty of Dentistry, Department of Oral & Maxillofacial Surgery, Gaziantep

Abstract

Introduction: Rhabdomyosarcoma is a malignant tumor of childhood. It arises from mesenchymal cells differentiating into skeletal muscle.

Case-Report: A 17-year-old female patient referred to our institution, biopsy was taken from wound area thought to have developed due to traumatic occlusion in the left cheek and sent for histopathological evaluation. In the postoperative 1st week, a growth of approximately 4 cm was observed in relevant tissue. Since histopathological examination came with diagnosis of "granulation tissue", he was called for a control one week later. It was observed that the growth increased to 8 cm in 2nd week. In the second biopsy, samples were taken from different parts of tissue. Histopathological report this time was concluded as "Embryonal rhabdomyosarcoma".

Conclusion: If the patient was sent with the diagnosis of cheek bite with a treatment protocol including preventive nutrition and restorative arrangements, rhabdomyosarcoma would not be diagnosed at an early stage.

Keywords: rhabdomyosarcoma, embryonal, neoplasm

Introduction

Rhabdomyosarcoma (RMS) is a malignant tumor of mesenchymal origin first described by Weber in 1854. (1) RMS constitutes 20% of all solid tumors seen in childhood, originating from embryonic mesenchymal cells that can differentiate into skeletal muscle. (2,3) It is more common in boys (58.4%) than girls. (4) The survival rate of %25 only with aggressive surgical treatment has been increased to %70 with multiple treatment protocol provided by inclusion of radiotherapy and chemotherapy. Although approximately 40% of the RMS cases are located in head and neck region, intraoral appearance is rare. Paranasal sinuses and neck are the most frequently affected areas in the head and neck region. (6)

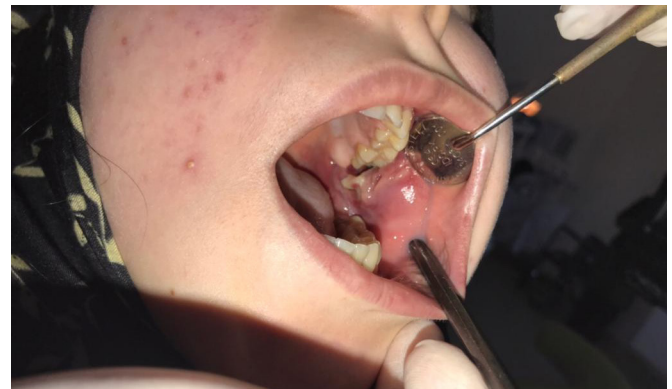Case Report

A 17-years-old female patient, who was referred to us from another institution, had a complaint of cheek biting, thought to be due to traumatic occlusion in the left cheek. After clinical and radiological examination, it was observed that the third molar teeth did not erupt, and it was learned that she had no complaints other than pain due to cheek biting while chewing for about a month.

A biopsy was taken from the scar-like tissue of approximately 1 cm in the posterior region of the left cheek mucosa (Figure-1). In the first postoperative week, a growth reaching approximately 4 cm in size was observed in the relevant tissue (Figure-2), even the biopsy result came as "granulation tissue". A soft diet was recommended and she was scheduled for control in the second week. It was observed that the mass grew even more

and reached a size of approximately 8 cm (Figure-3).

Considering this rapid and excessive growth, it was decided to perform a second biopsy and the biopsy was performed from 3 different parts of the mass; the largest being 2 cm and the smallest 1 cm. The result of the second biopsy came as "embryonal rhabdomyosarcoma". Following the surgery patient was directed to the Department of Oncology for a multiple treatment protocol, including chemotherapy and radiotherapy.



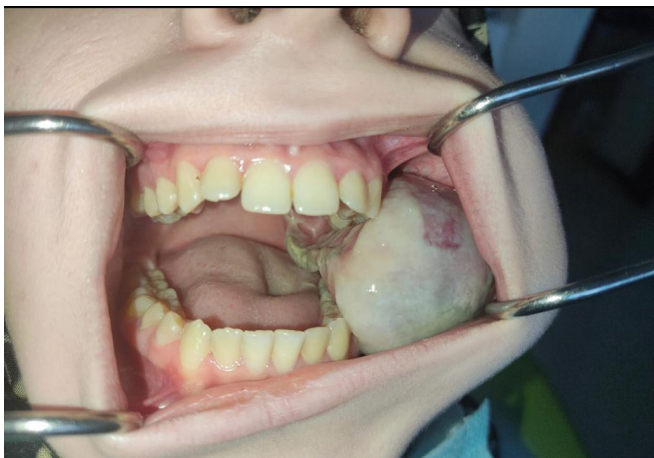
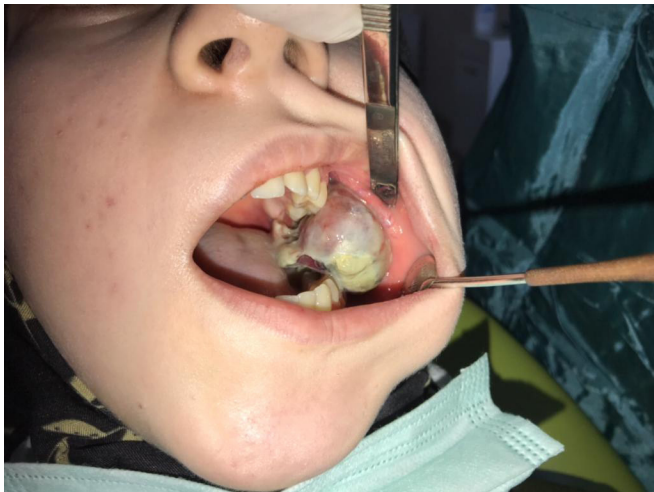Corresponding Author: Tolga BAYAR

Research Assistant

Address: Gaziantep University Faculty of Dentistry, Oral and Maxillofacial Surgery, Diyarbakır/Turkey
Karşıyaka Mah. 4002 Sk. No:12 Kapı No: 48 Karaköprü / Şanlıurfa

Mobile: +90(536) 435 66 42

E-mail: dttolgabayar@gmail.com



References

1. Stuart A, Radhakrishnan J. Rhabdomyosarcoma. *Indian J Pediatr.* 2004;71:331-7.
2. Weiner E. Soft tissue sarcoma, in Carachi R, Azmy A, Grosfeld JL (eds): *The Surgery of Childhood Tumors*, Oxford University Press, 2009, pp:210-242.
3. Ruymann FB. Rhabdomyosarcoma in children and adolescents. A review. *Hematol Oncol Clin North Am* 1987;1:621-654.
4. Mollen KP, Rodeberg DA. Diagnosis and treatment of rhabdomyosarcoma. in Coran AG, Adzick NS, Krummel TM, et al. (eds): *Pediatric Surgery*, Philadelphia, Mosby, 2012, pp:491-501.
5. Edland RW. Embryonal rhabdomyosarcoma. *Am J Roentgenol Radium Ther Nucl Med* 1965;93:671-685.
6. Seth T, Kempert P. Embryonal rhabdomyosarcoma of lower lip. *Indian Pediatr.* 2004;41:858-9.
7. Birch JM, Varley JM, Kelsey AM. Soft tissue sarcomas in 20 families with Li-Fraumeni syndrome. Third International Soft Tissue Sarcoma Congress, Stuttgart, Book of Abstracts 1997;15.
8. Dagher R, Helman L. Rhabdomyosarcoma: An overview, *Oncologist.* 1999; 4: 34-44.
9. Parham DM. The pathologic classification of rhabdomyosarcomas and correlations with molecular studies. *Mod Pathol.* 2001;14: 506-14.
10. Stobbe GC, Dargeon HW. Embryonal rhabdomyosarcoma of head and neck in children and adolescents. *Cancer* 1950;3:826-836.

Results

In this case, RMS would not be diagnosed at an early stage if the patient had been treated for cheek biting diagnosis with nutritional and restorative adjustments. Patients should be thoroughly examined. Biopsy results alone should not be determinative and clinical manifestations of the case should be followed carefully to avoid the diagnostic handicaps. Our case led us to the diagnosis of a malignant tumor which could easily be overlooked if careful follow-ups are not provided.

Discussion

The frequency of RMS increases between the ages of 2-6 and 10-18. [7] Our patient was 17-years-old.

Hearing disorders, vision, speech, swallowing and respiratory problems may develop when RMS is located in the head and neck region. [8] In the presented case; the preoperative complaint was pain caused by cheek biting and postoperative complaints were speech disorder and facial asymmetry due to the growth of the mass.

Horn and Enterline divided RMS into four histological subtypes as embryonal, botryoid, alveolar and pleomorphic. [9] Embryonal RMS is the most commonly seen type from birth to childhood with 60% survival rate, and mostly located in the head and neck region. [2,10]

Although 40% of RMS is seen in the head and neck region, intraoral location is very rare. [6] The most commonly affected tissue intraorally is the soft palate. [1] In our case, RMS was seen in the oral cavity and cheek mucosa, presenting an extremely rare location.